

**Zirkonzahn®**

*Human Zirconium Technology*

**PLANESYSTEM®**

*Analysis, acquisition and transfer of referenceable individual patient information*

Enrico Steger, MDT



## WHEN IT COMES TO HEALING ...

*... only the best is good enough. For this reason, we decided to work with my long-time colleague, Udo Plaster, MDT, in the realm of patient and model analysis. His PlaneSystem® is a transfer method that respects and recognises the patient as a person. Whether we choose the digital or the traditional route in the preparation of dental restorations, the accurate and individual recording of patient data by the PlaneSystem® will pave the way for the pursuit of complete health. We have integrated the PlaneSystem® to 100% into our Zirkonzahn workflow and are constantly working with Udo on new ideas and improvements.*

*Udo Plaster, MDT*



## COMPLEX RESTORATION

*Collecting, understanding, allocating and processing information – this is our way to a perfectly fitting dental prosthesis. In addition to dental diagnostics, a dental technical analysis or physical diagnosis is carried out. The work steps based on this analysis also led to a high level of satisfaction and a relaxed smile for the patient whose case is presented on the following pages.*

*The patient was provided with an implant-supported prosthesis in the edentulous mandible. In the upper jaw he was wearing a full denture. Six implants were placed to anchor the fixed prosthesis. Although the patient did not complain about functional problems, it was clearly visible that the dimensions of the existing denture did not match the patient-specific conditions. Actually, the new fixed restoration in the upper jaw was now to be adapted to the lower jaw restoration. At this point, the patient contacted us for a second opinion. We explained to him the necessity to first work out the occlusal plane individually in order to be able to fabricate the dental restoration based on it. The restoration in the mandible had to be adjusted later to the correct plane. After the initial consultation, the patient decided to entrust his prosthetic rehabilitation to us.*

*Dr. Siegfried Hrezkuw*



*Each person has his/her own dental history and the own solution approach. The manufacture of dental restorations requires an individual analysis of the human system. This results in a pool of reproducible data/information as an individual guideline for the production of a long-lasting, accurately fitting and aesthetic dental prostheses.*

*Dr. Siegfried Hrezkuw, Udo Plaster, MDT*

## GATHERING OF INFORMATION

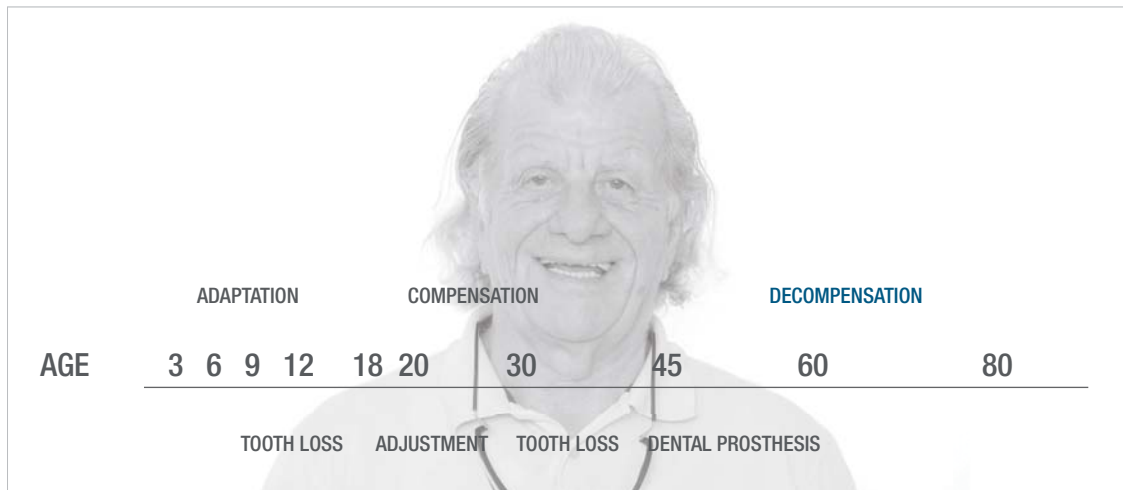
### FIRST DENTAL TECHNICAL ANALYSIS

*The collection of information begins with a patient interview regarding the dental history; clarified are, for example, the following points:*

- *Orthodontic treatments*
- *Surgical interventions*
- *Tooth losses*
- *Existing denture*
- *Patient needs in connection with the new prosthesis*

### DENTAL HISTORY

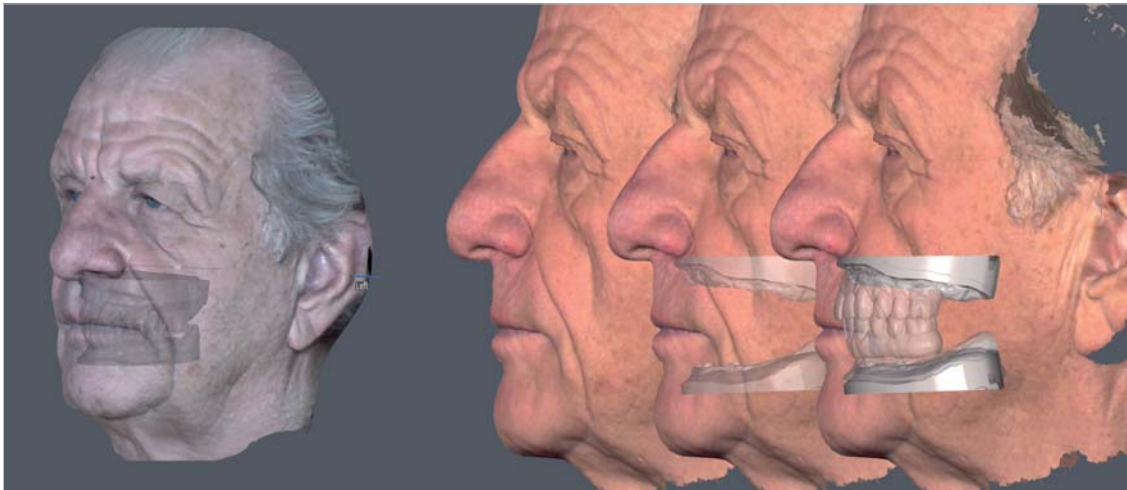
*The patient gradually lost his teeth over the last few decades. He was wearing different kinds of dental prostheses. He is currently wearing a full denture in the maxilla and a fixed implant-supported restoration in the mandible. Now he would like to have a fixed maxillary restoration. Six implants had already been placed. Timeline: Dental history of the patient as well as general adaptation phases and compensation phases.*





## FACIAL ANALYSIS

*Preparation for photographs and 3D digitisation of the face with the Face Hunter facial scanner.*

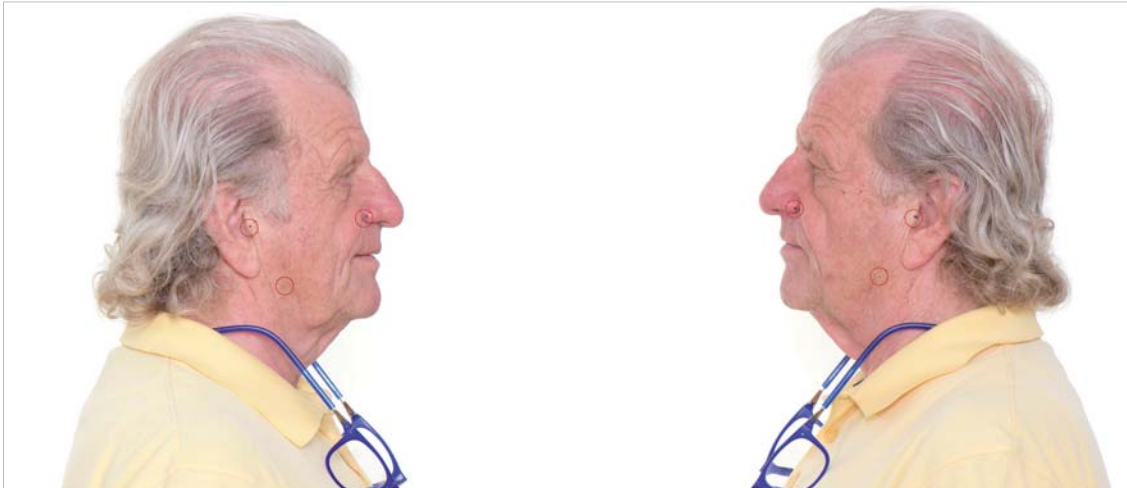

*The situation models shown on the face scan reveal the high vertical dimension. The alveolar ridge in the upper jaw is severely atrophied. The occlusal plane in the mandible drops dorsally. Each intervention into the stomatognathic system after completion of the growth (e. g. dental prosthesis, orthodontics) is compensated by the body elsewhere. For this, seven compensation points (Hergenröther, 2015) can be defined on the skeleton.*

## ANATOMIC LANDMARKS

### ANATOMIC LANDMARKS

*Landmarks (anatomic orientation points) are captured both on the face (facial landmarks) as well as on the model (cranial landmarks). The reference points are used as an orientation when dividing the dimensions.*

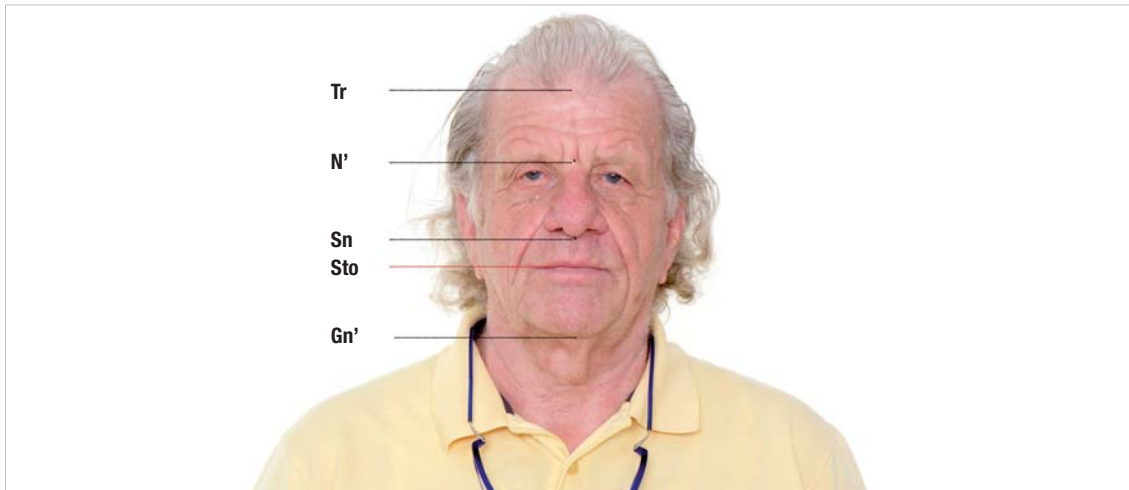


*The anatomic landmarks are identified on the patient's face.*

*This involves defining orientation points on the skull that can be reproduced at any time (even when the patient is edentulous). Seen from the sagittal view, these are the ala points (ala of the nose) at the right and left, the tragus (outer auditory canal) and the jaw angle.*



*At the front, nasion and subnasal point are marked as anatomic landmarks.*



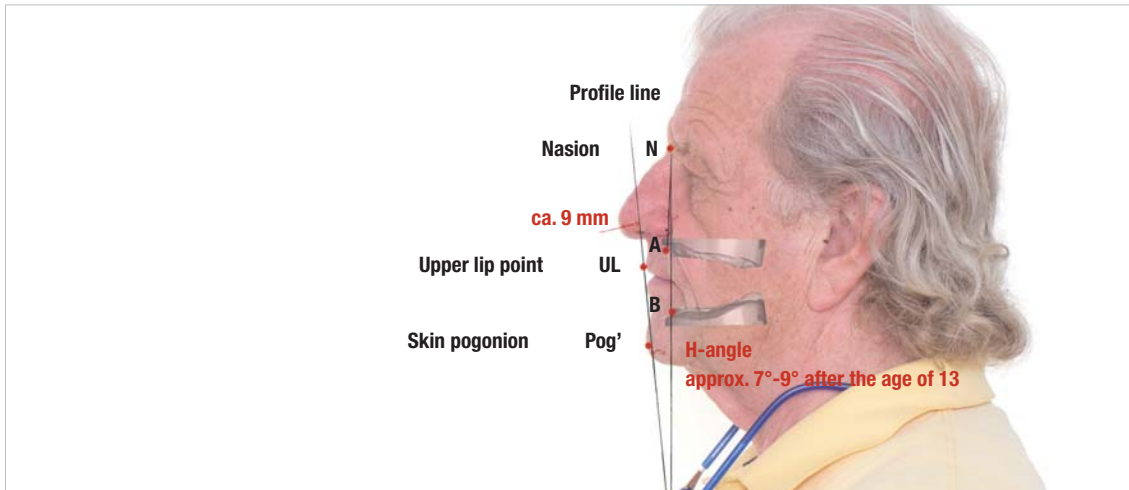
*Division of the face into different planes.  
The most important point here is the stomion\*.*

*\*Stomion: contact point of the upper lip to the lower lip when articulating the “m-sound” and/or when the lips are in a relaxed position (without occlusal contact).*



To determine the centre of the skull, a template is inserted into the patient's mouth and the centre of the skull is marked on the palate. Ala points, nasion, spina, raphe mediana – due to the natural asymmetry of a face, the lines never match exactly (see left picture). The image is captured in the Natural Head Position\* (NHP).

\*NHP: natural position (without exogenous influences) where the patient is in equilibrium and looks himself/herself in the eyes in the mirror.

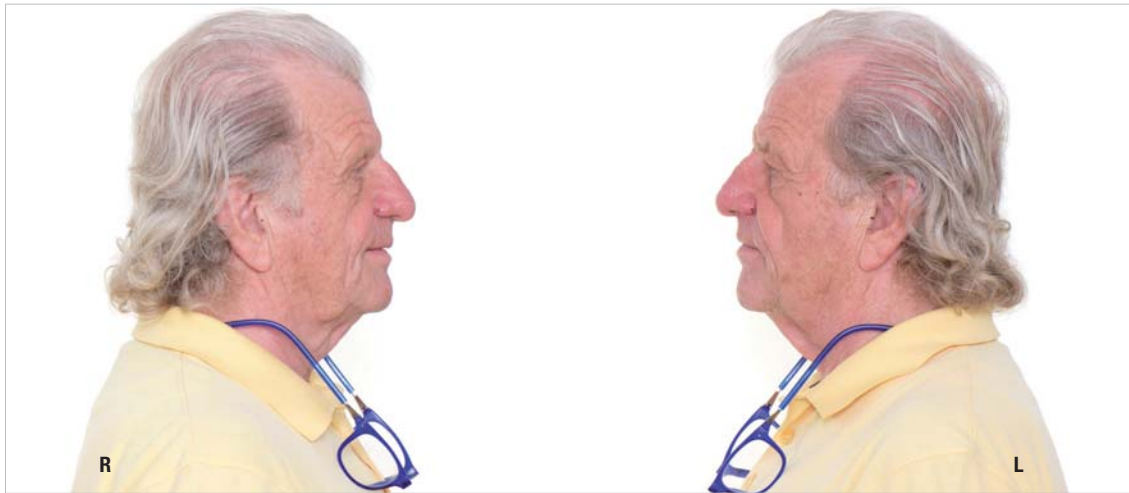

## PROFILE ANALYSIS BY HOLDAWAY\*

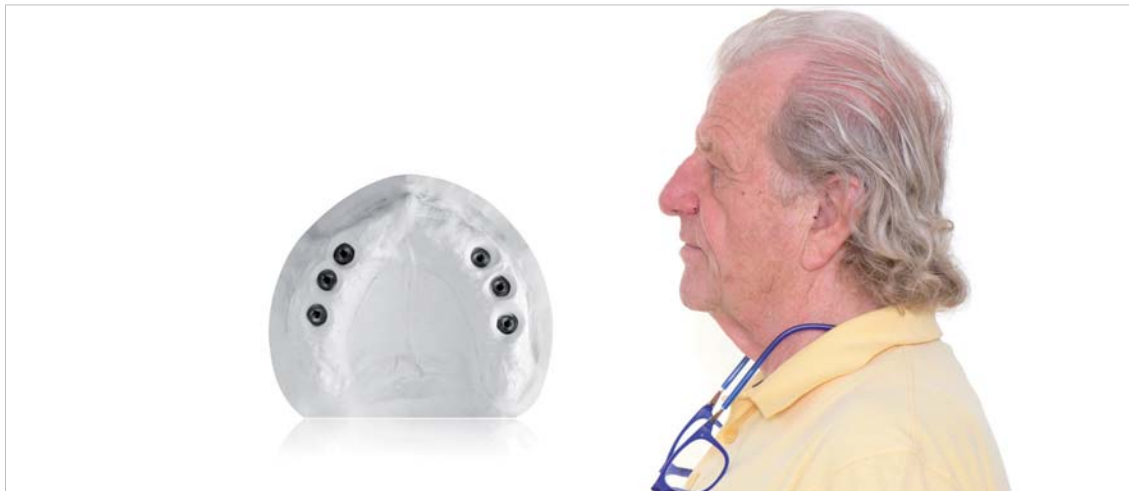For the profile analysis, a photo is imported into the Zirkonzahn.Scan software and displayed together with the situation models (without dental prosthesis). In order to obtain a profile image at the correct height (vertical dimension), the patient should hum the letter “m” (without occlusal contact) during the capture.

\*Holdaway line: connecting line between pogonion, upper lip point and intersection on the nose (usually 7 mm to 9 mm). The resulting Holdaway angle lies between 7° and 9° (after the age of 13).



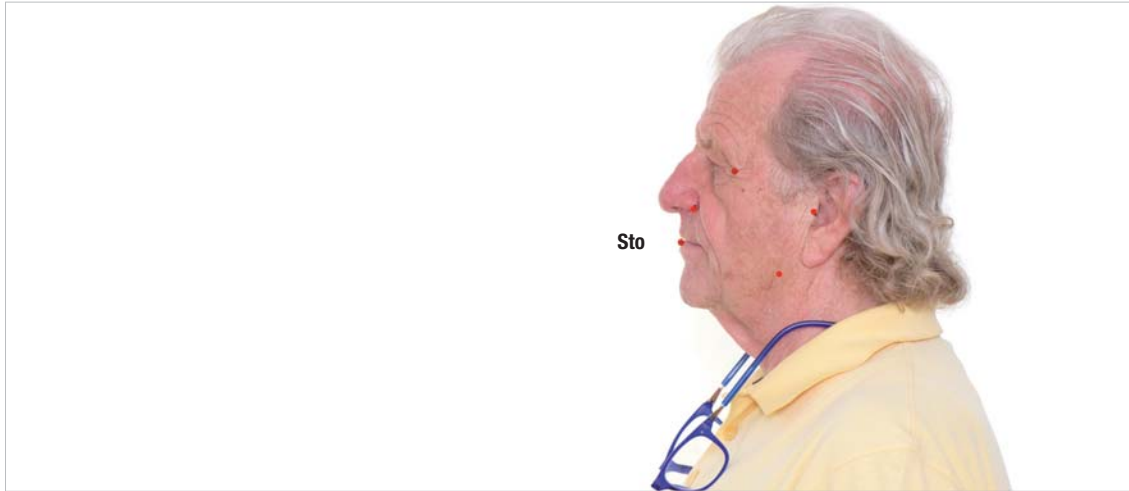


*Analysis of the right and left half of the face*

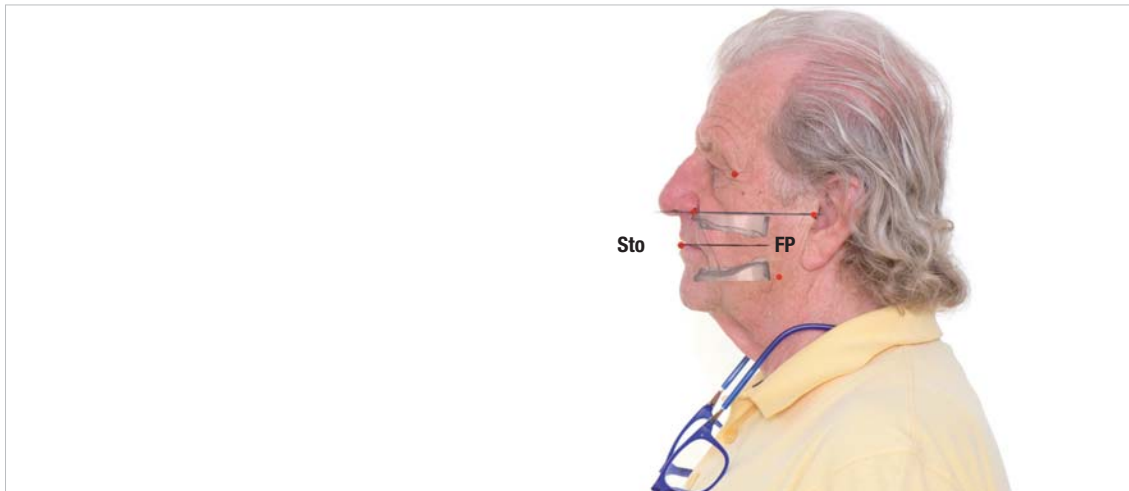

*How can the landmarks\* now be transferred onto the model or how can the spaces on the toothless jaw be divided?*

*\*Landmarks: anatomic orientation points on the face (facial landmarks) and on the model (cranial landmarks) for dividing the dimensions (tooth position, tooth size).*

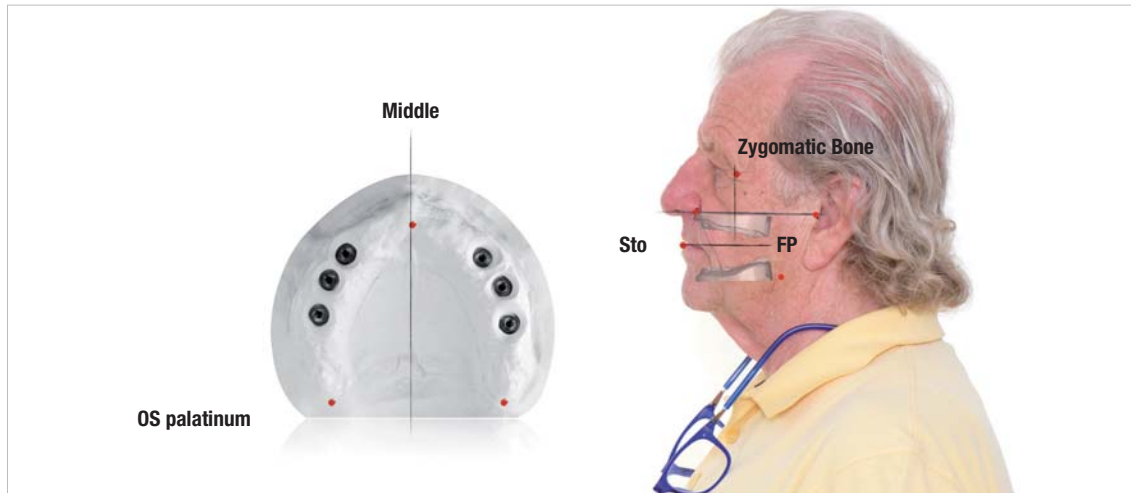


*The landmarks are marked sagittally on the profile picture. Most important point: stomion.*

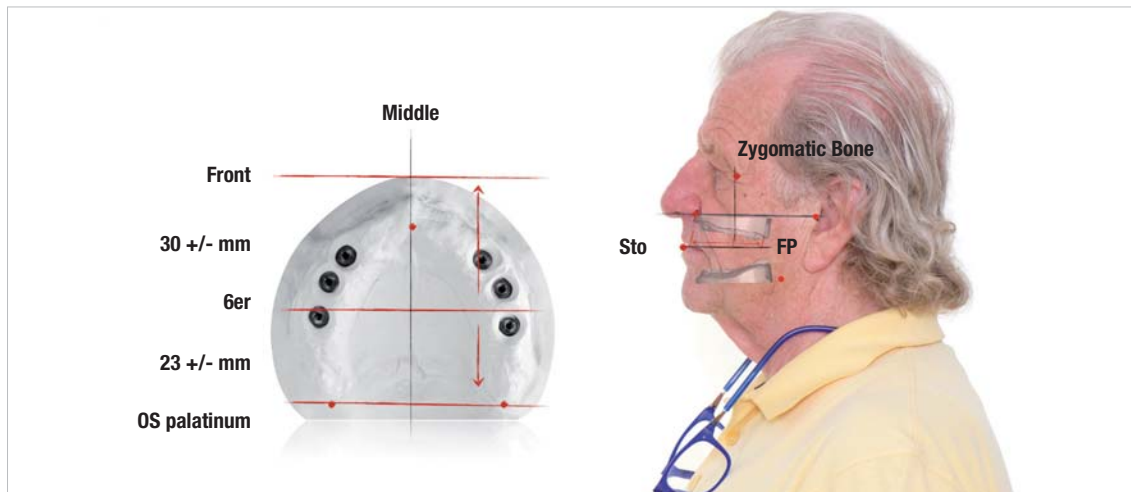


*As a parallel line to the ala-tragus\* line, a line emerges from the stomion (Sto): the functional plane (FP).*

*\* Ala-tragus line = connecting line from the ala nasi (ala of the nose) to the tragus (entrance of external auditory canal)*

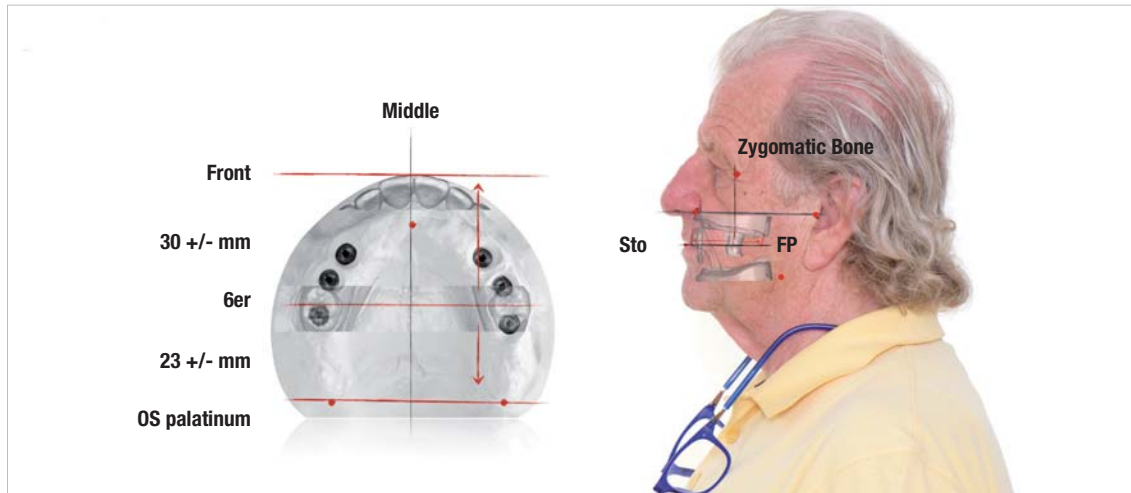


*A vertical line is drawn from the marked point on the os zygomaticum to the functional plane. The intersection of this line with the ala-tragus plane indicates the position of the upper molar.*

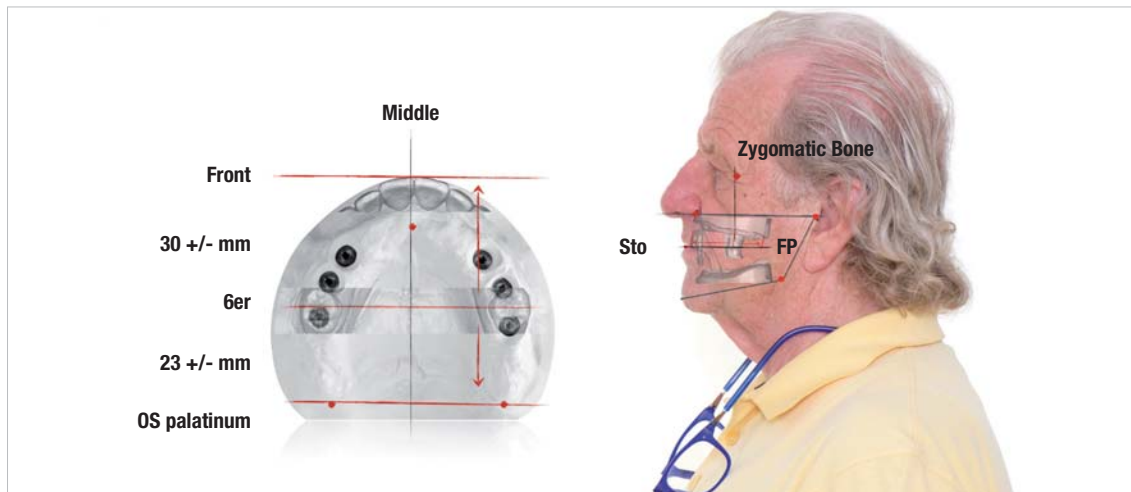


### **DIVISION OF THE SPACES ON THE MODEL**

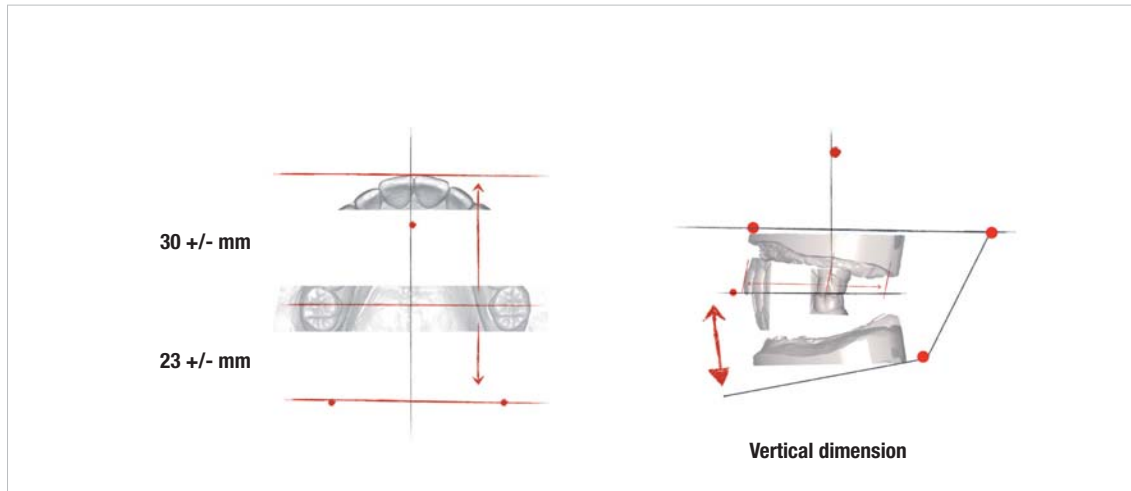
*The information obtained is transferred to the model. The midline and the hamulus points (left, right) on the opalatinum are used as landmarks on the model. The previously determined position of the molars is marked as a line on the model. This results in verifiable dimensions as a reference point for the manufacture of the dental restoration.*



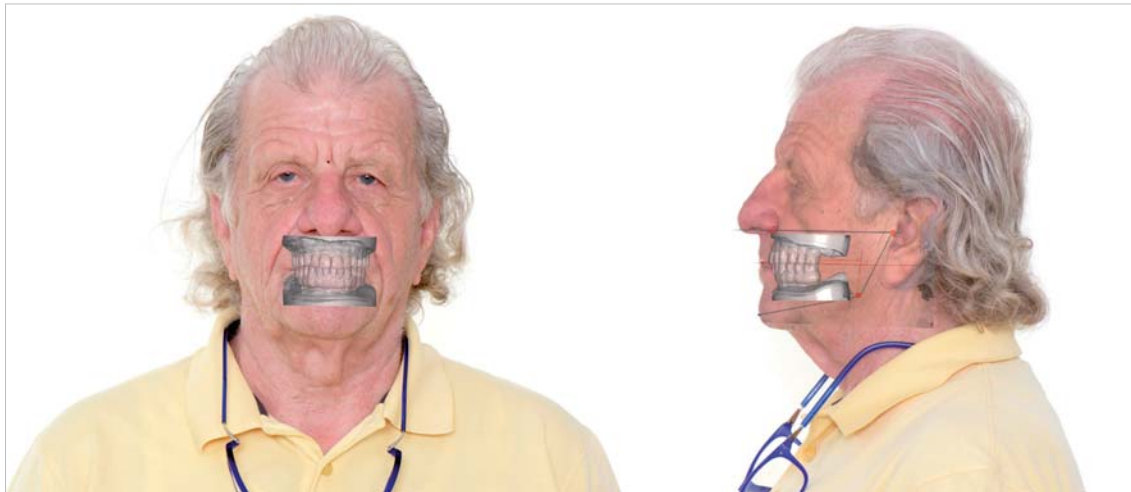*In the software, the anterior teeth and the first molars are displayed in their desired position. Up to this point we only work on the upper jaw without taking the lower jaw as a reference.*



*In order to assign the lower jaw model to the upper jaw model, the bite height is required. For this purpose, the jaw angle is marked and an orientation value is retrieved. Important information can also be obtained from the position of the upper molars. The molar is like a water level. If the angle opens towards the front like a fan, a lot of growth can be expected in this area. If the angle opens only slightly towards the front, the growth is more pronounced in the posterior area.*



*The graph shows the presumed vertical dimension between the upper and lower jaw model, which has been determined from the available “jaw angle” information. The bite height is always worked out together with the patient (physically and muscularly).*



### PREVIEW TOOTH RESTORATION

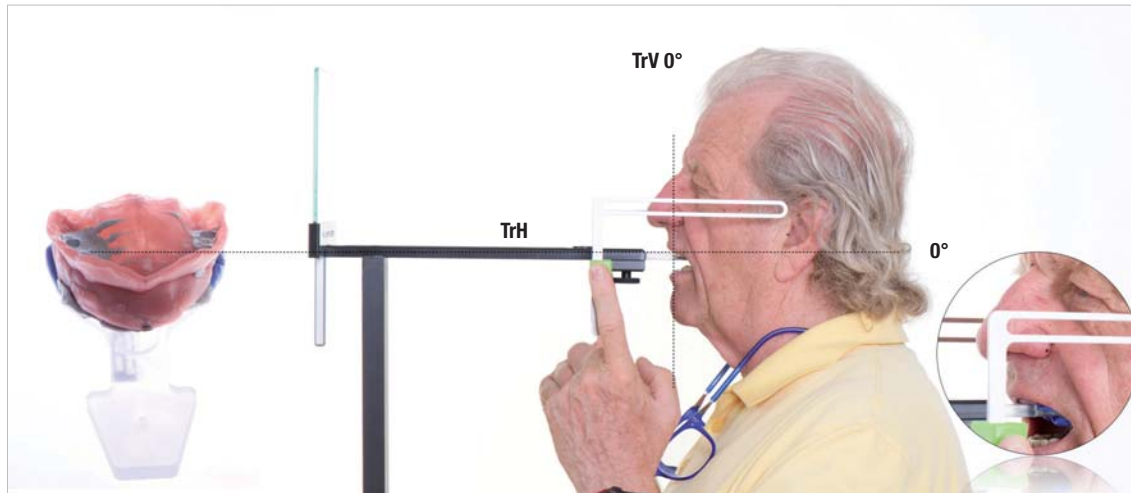
*For a better illustration, the planned dental prosthesis is already shown on this picture. The vertical dimension must be strongly increased.*

## REFERENCED TRANSMISSION OF THE LOWER JAW

*How is the determined information now transferred in such a way that the tooth restoration can be manufactured? The aim is to fix the maxillary model in the articulator in a patient-individual position and to assign the mandibular model based on the centre, height and horizontal position determined by the physiological perception. The PlaneFinder® is used for this purpose.*

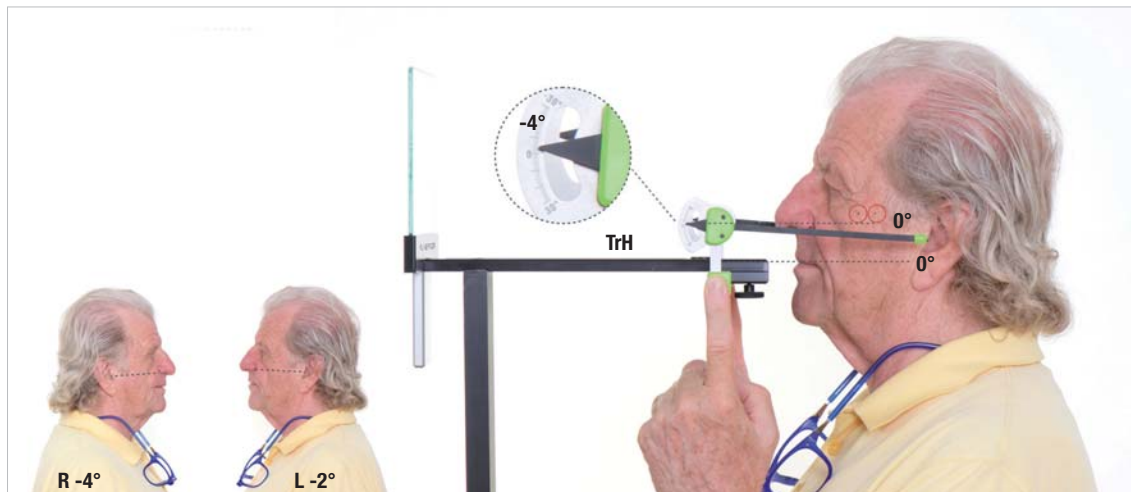


*The anatomic landmarks marked on the photo.*

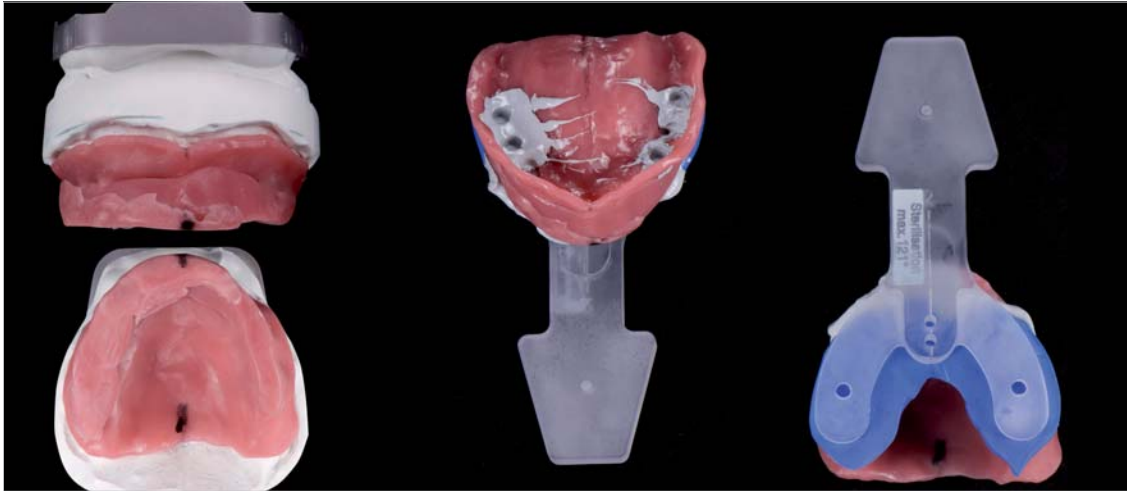


### POSITION OF THE MAXILLARY MODEL

*The PlaneFinder® uses two zero lines defined in three-dimensional space (True Vertical, True Horizontal) as reference points/lines. The template is fixed to the healing caps in the upper jaw for a reliable determination of the position.*



*The position is registered and encrypted on the tray. The red circles below the os zygomaticum are the synchronisations of the zero line, used among other things as a reference for the face scan. The ala-tragus angle measured in this case is flat or even negative.*



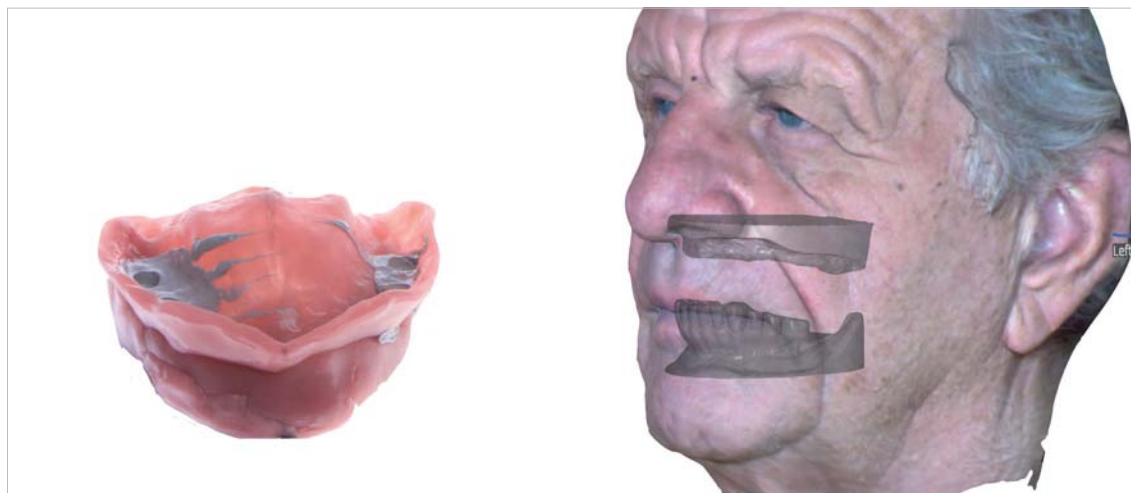
*With the tray and the coded position, the upper jaw model is now transferred to the articulator in the correct three-dimensional dimension.*

## PHYSICAL DIAGNOSTICS

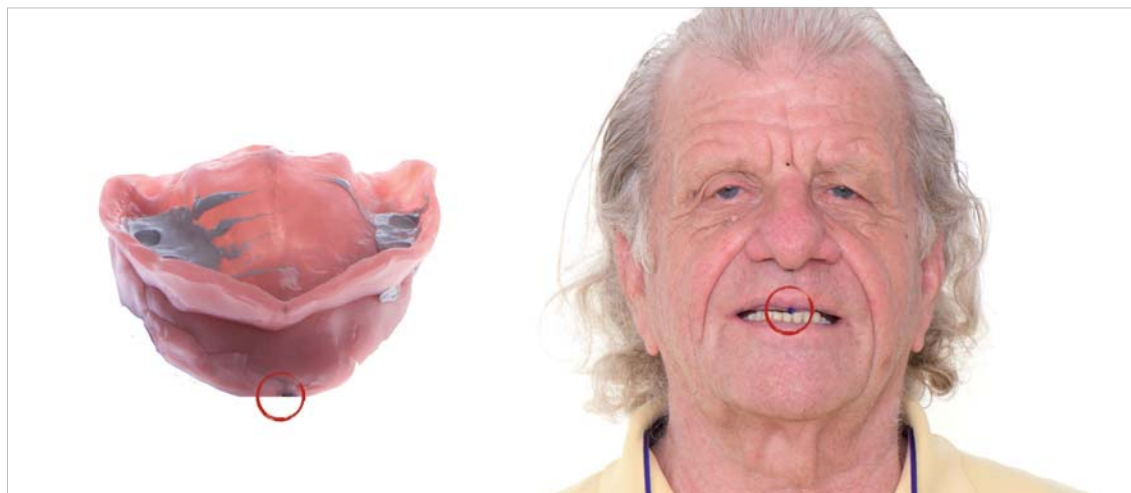### DETERMINING THE VERTICAL DIMENSION

*The physiological bite height cannot “simply” be read with the obtained data, but must be worked out with the patient as part of the physical diagnosis.*



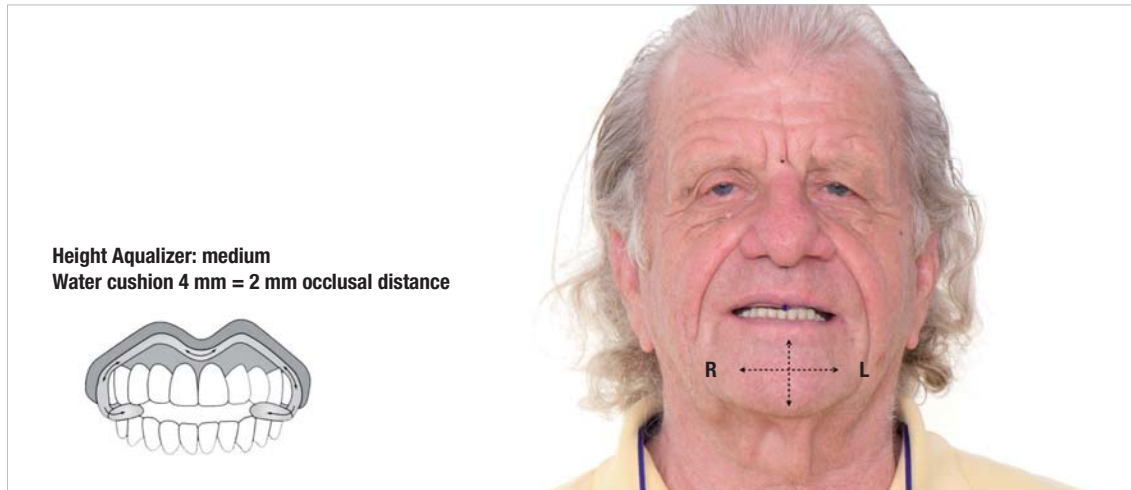


*Preparation for the physical diagnostics.*



*The upper jaw template is used to determine the bite height and speaking distance together with the patient.*

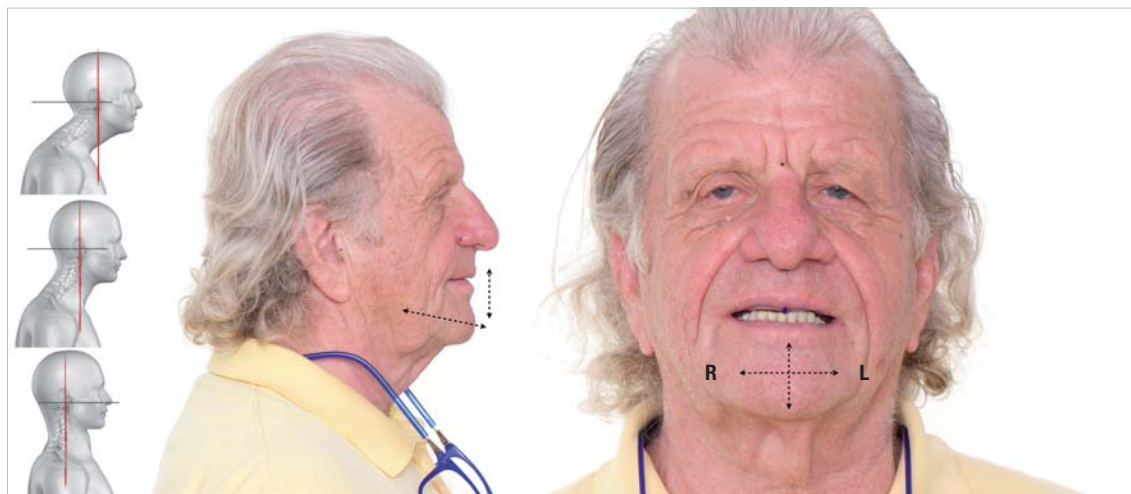
## NEUTRALISATION



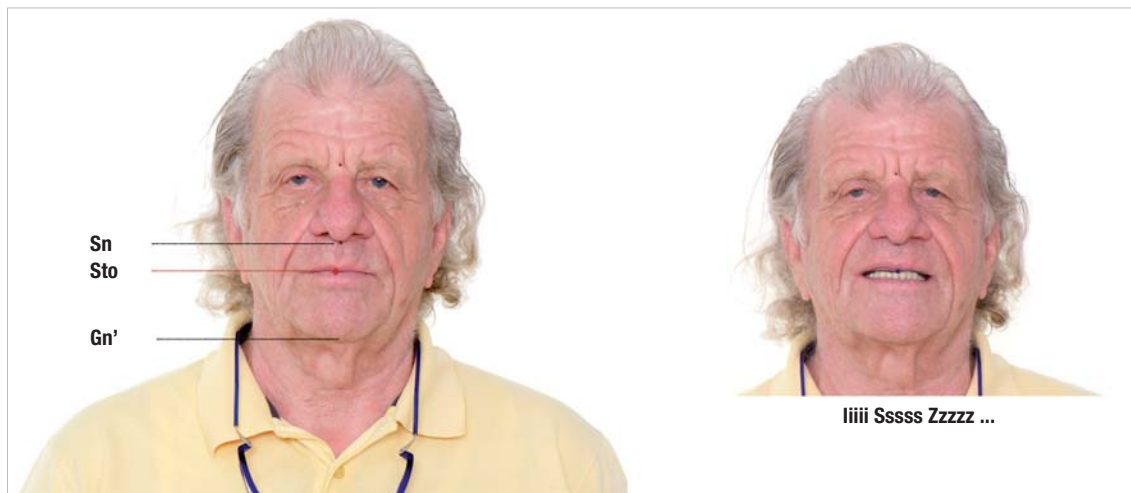### AQUALIZER: NEUTRALISATION

*To determine the lower jaw position, a water cushion\* is first used. The cushion height results from the speaking distance (speech analysis with template) and the information of the model analysis. A medium sized pillow is chosen. With the Aqualizer the patient finds a comfortable position.*

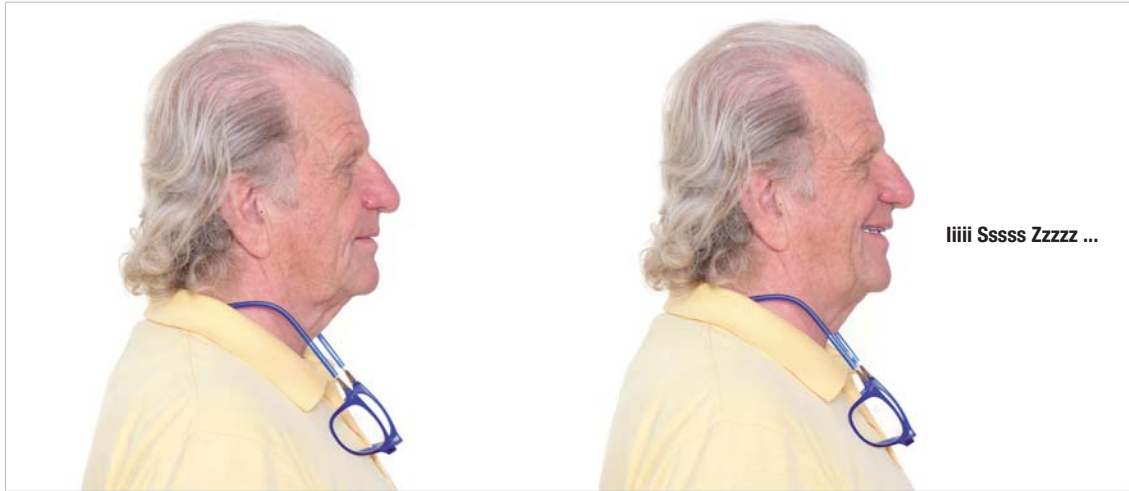*\*Aqualizer: Flexible occlusal aid consisting of two cushions filled with liquid. The cushions are connected and "communicate" with each other after interocclusal placement.*



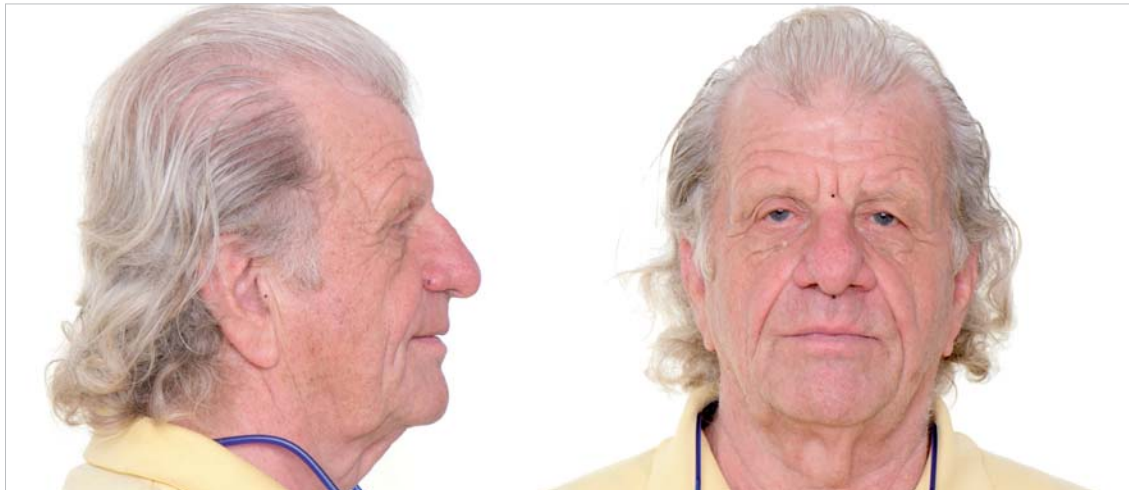*With the Aqualizer a stable middle is found.*




*The speech motor skills function well and are perceived as pleasant by the patient.*



*Checking the speech motor skills: sagittal view.*

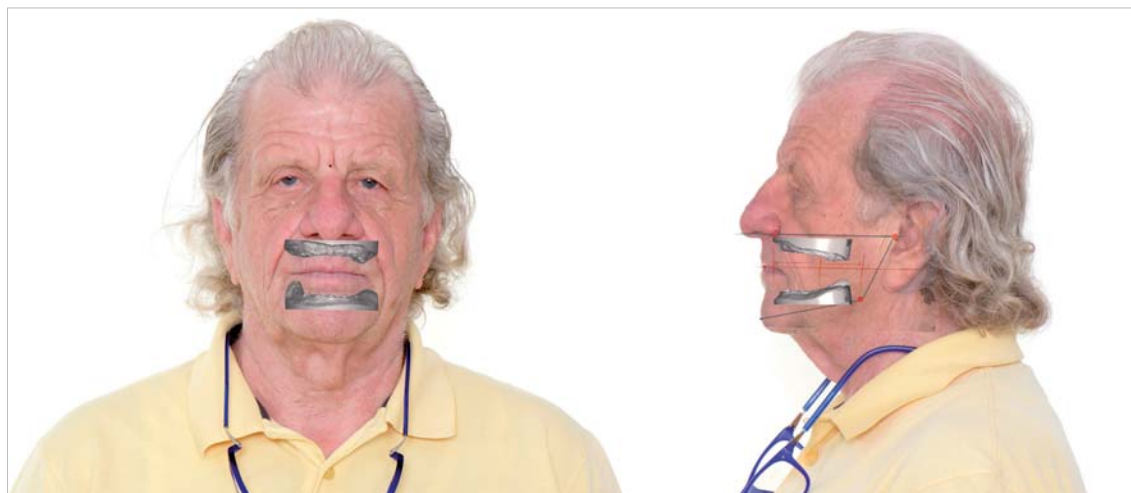

*Relaxed facial expression through perceptual-physiological determined center, height and horizontal positioning of the lower jaw in the skull. The patient positions himself. No exogenous factors influence the result.*




*For the articulation of the models, the fixing pin on the articulator is set to 0.*

*This bite height must not be changed on the articulator. The physiological bite height is always worked out with the patient and not identified on the fixing pin.*

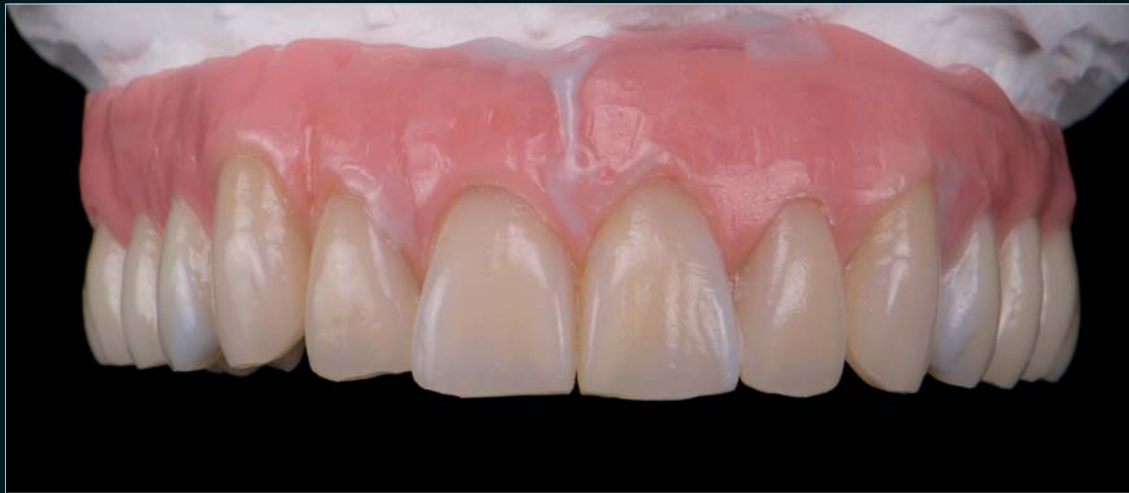

*Representation of the dimension between upper and lower jaw. This distance must be filled with the tooth restoration.*

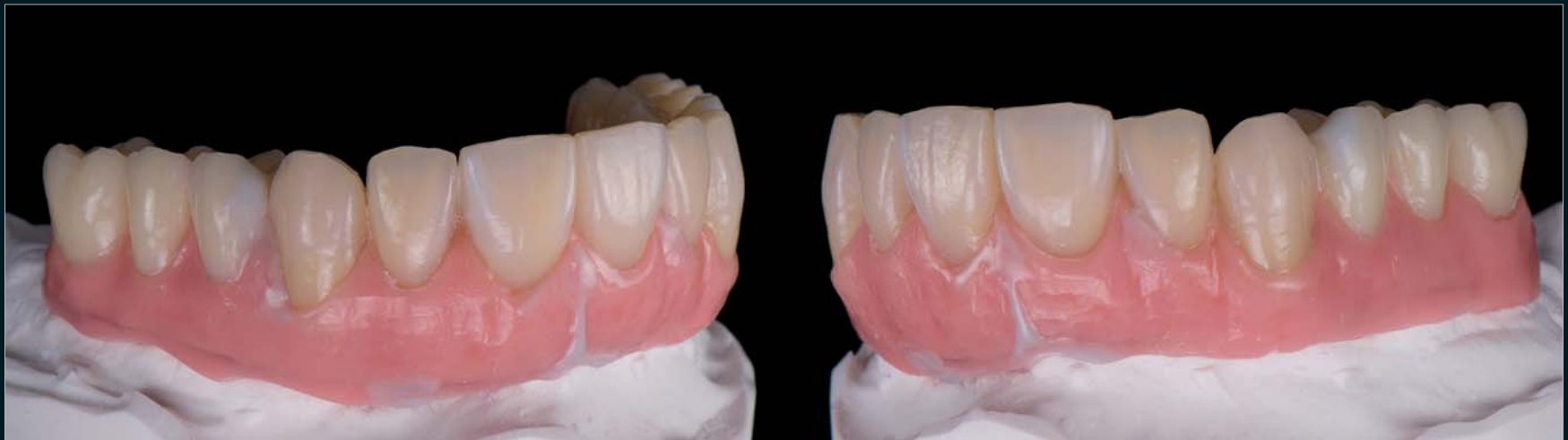## REALISATION



*In the first step, a prototype of the upper jaw restoration is to be produced. This can be done digitally or through the analogue elaboration of the situation on the patient.*



*In this case, the teeth are placed conventionally and a diagnostic set-up is prepared for the try-in in the patient's mouth.*





*Comparison: patient in the left picture with old denture and in the right picture with diagnostic set-up*

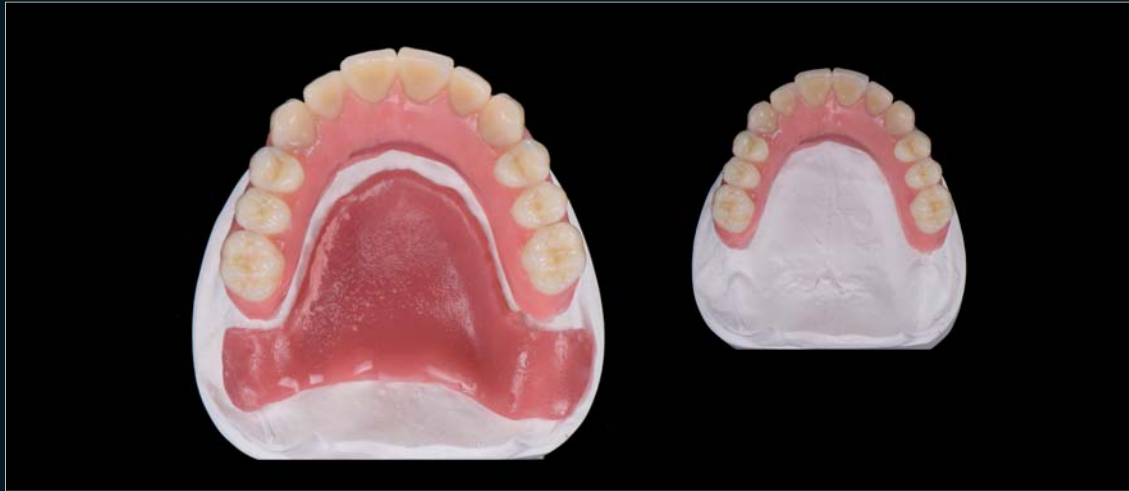

*The patient tests the diagnostic set-up in the mouth and evaluates the result in the mirror.*

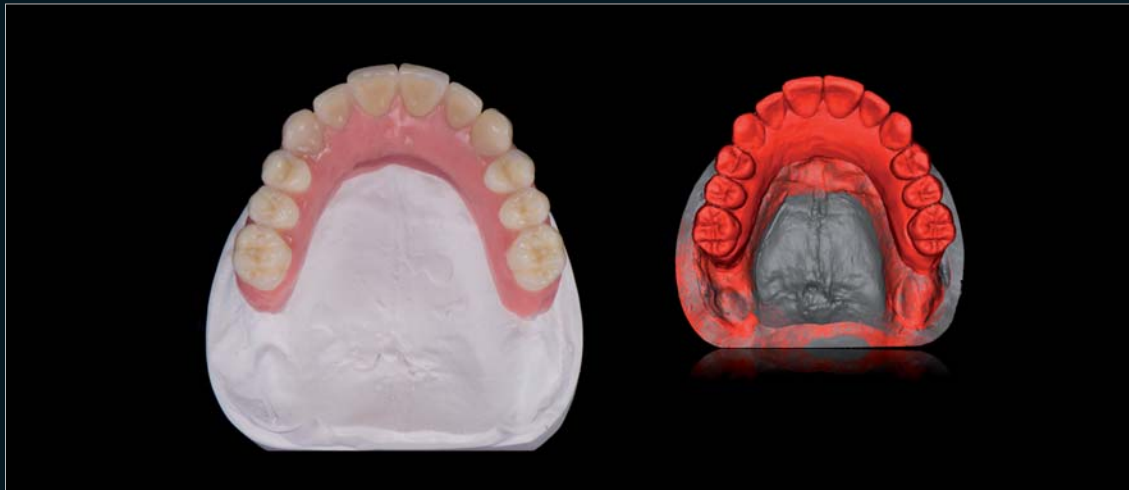

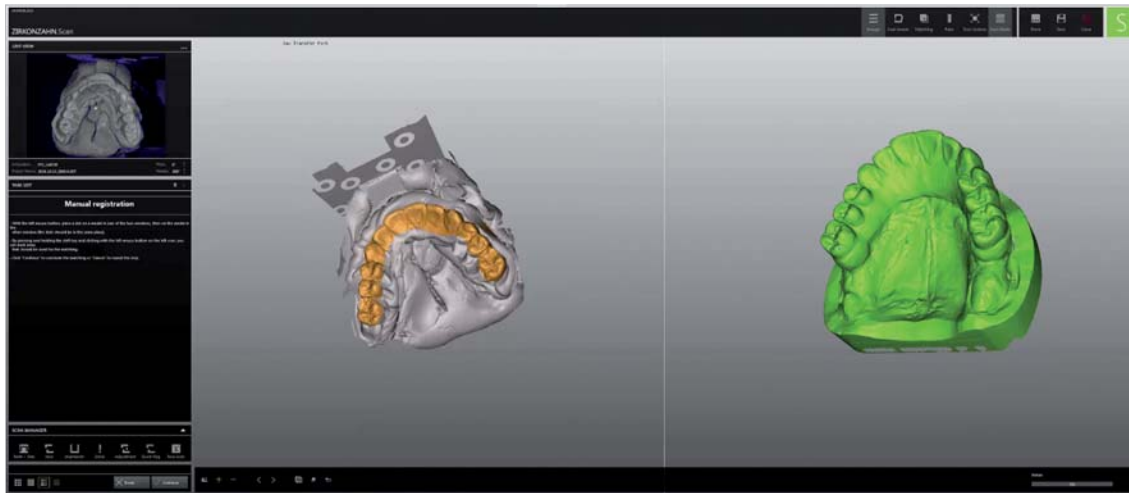
DIGITISATION OF PHYSICAL DIAGNOSTICS

*The dental arch is removed from the set-up.*



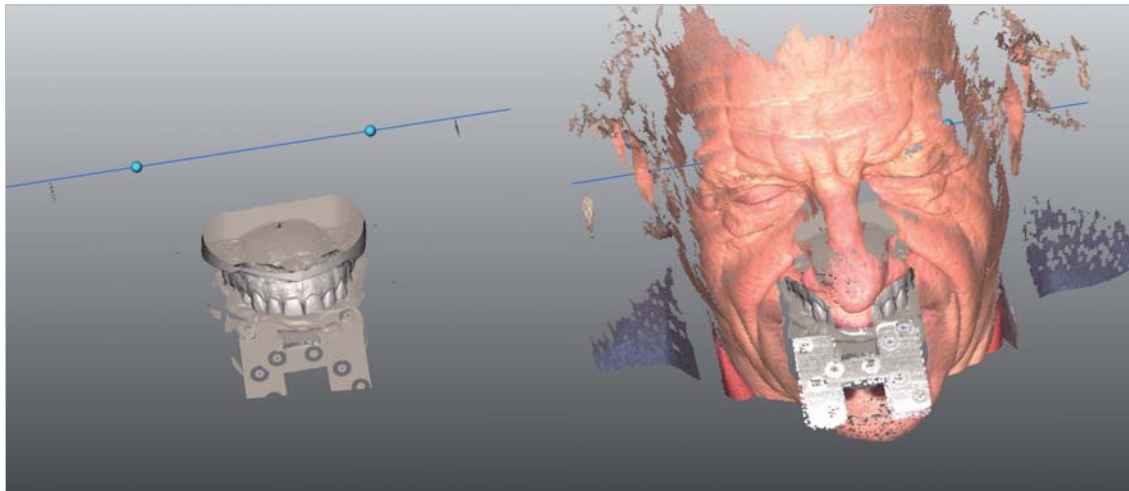
*After refining the dental arch, the situation is digitised in the S600 ARTI model scanner.*



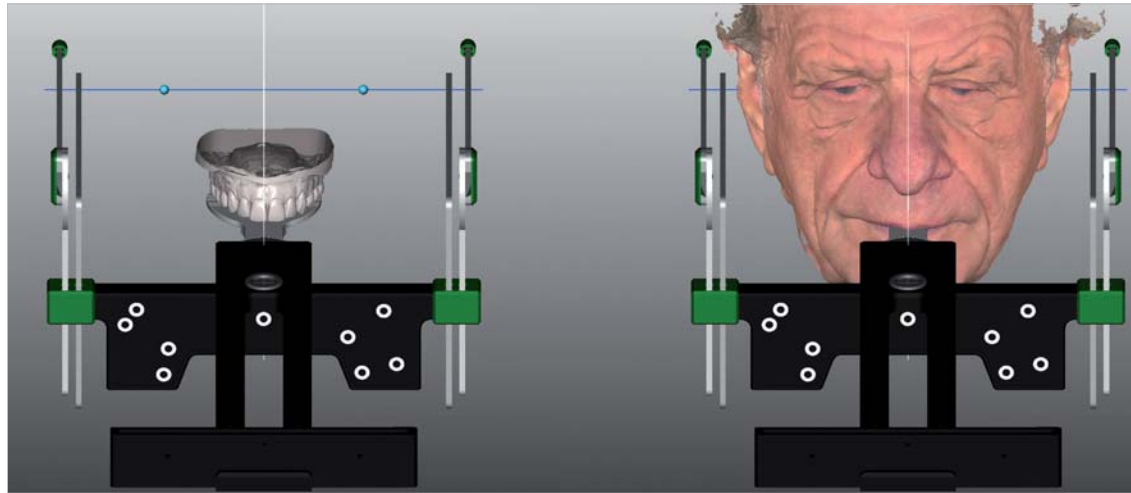


## SET-UP AND 3D FACE SCAN

*The diagnostic set-up is digitised and prepared for matching with the 3D face scan.*

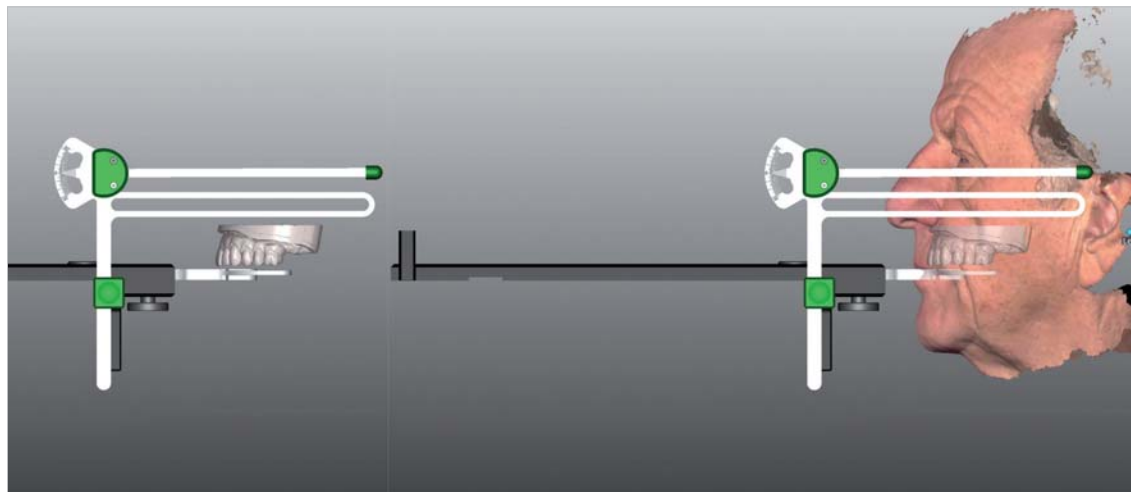


*Using the Transfer Fork, the upper jaw model can be positioned in the correct position in the facial scan. The analogue physical diagnostics was thus transferred 1:1 into the digital world or transferred into the facial scan without any loss of information.*

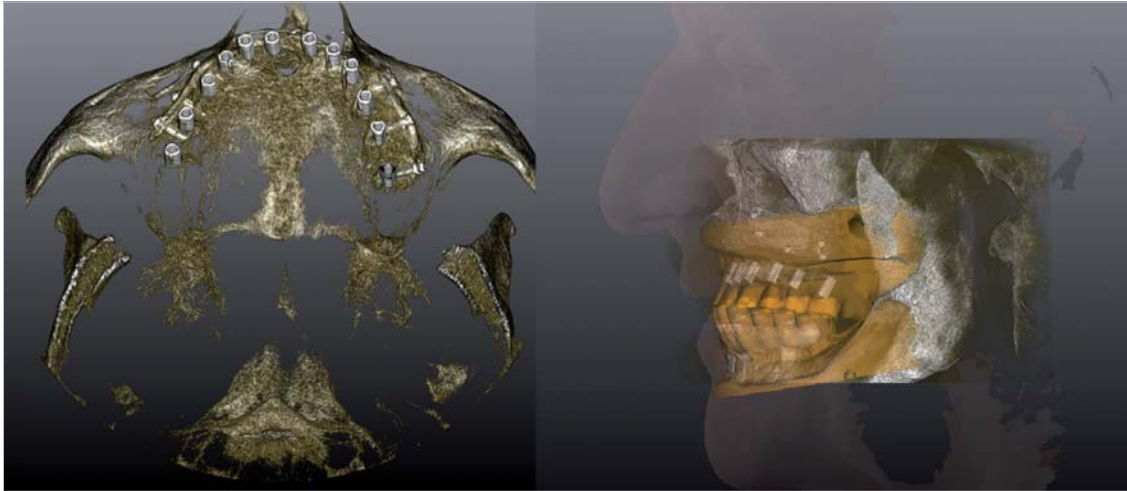


### 3D FACE SCAN

*Setting up the center (zero line) in the Zirkonzahn.Scan software.*



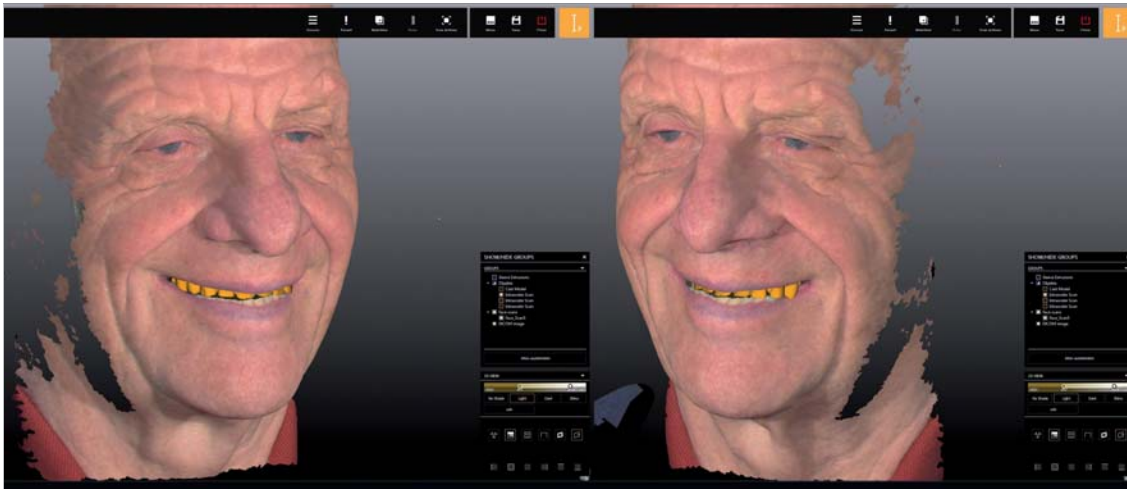*Setting up the planes (zero line) in the scan software. The analogue preparatory work can now be validated in the 3D face scan.*



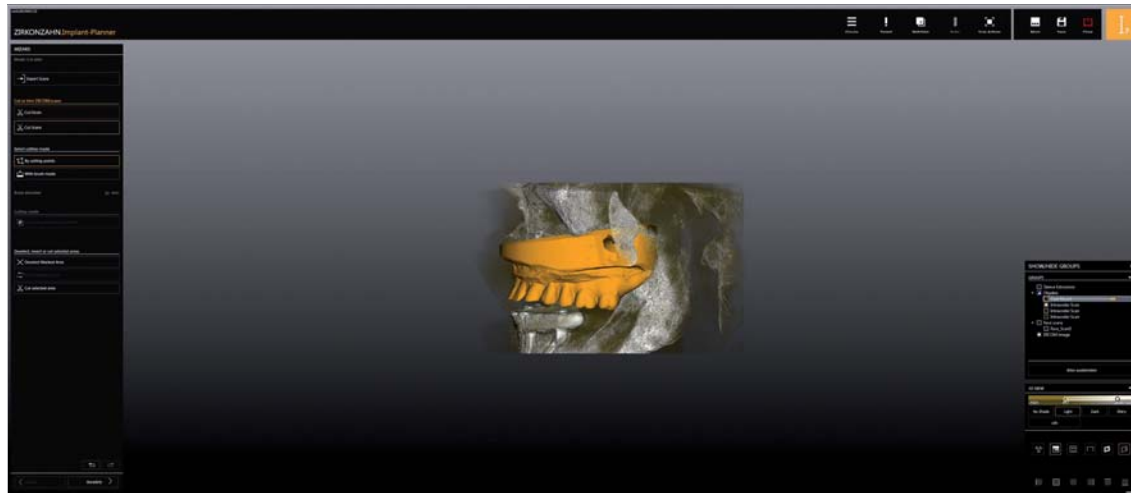## ANALYSIS OF THE EXISTING DENTAL PROSTHESIS

*Theoretically, the digital planning of the implant positions would now take place. In this case, the implants were already inserted. The DICOM data from this CBCT are loaded into the Zirkonzahn.Implant-Planner software.*

*\* Zirkonzahn.Implant-Planner: Implant planning software where all data (CBCT/DICOM, model, facial scan, etc.) are matched.*

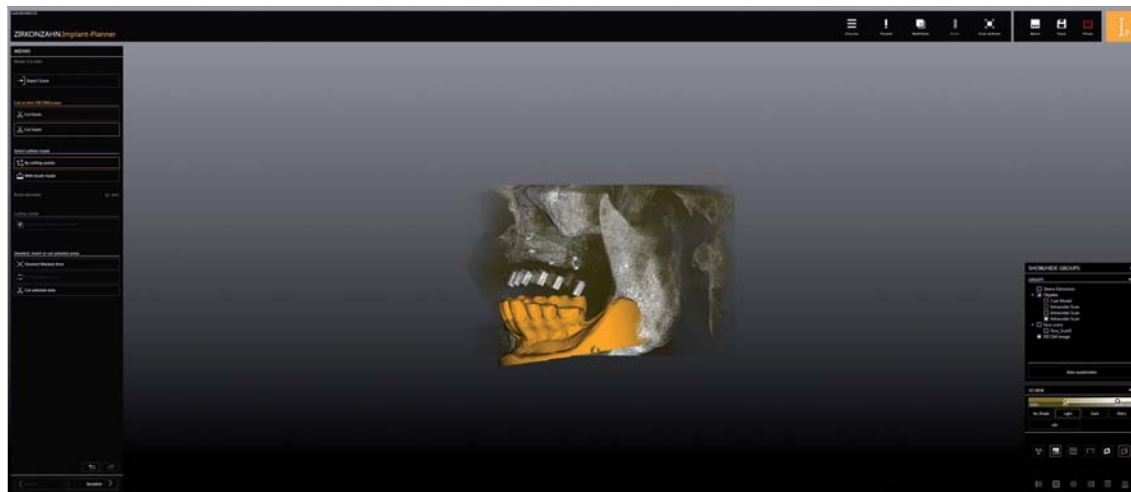

*The data record from the scan software has also been imported.*

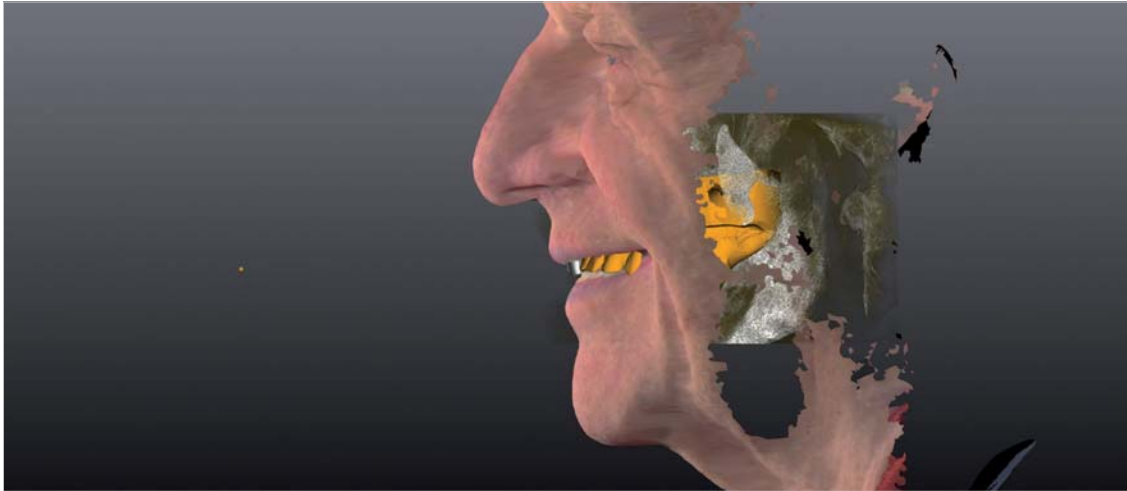

*Matched data (CBCT and STL):*

*The yellow model shows the situation of the old denture (full denture) in the upper jaw.*



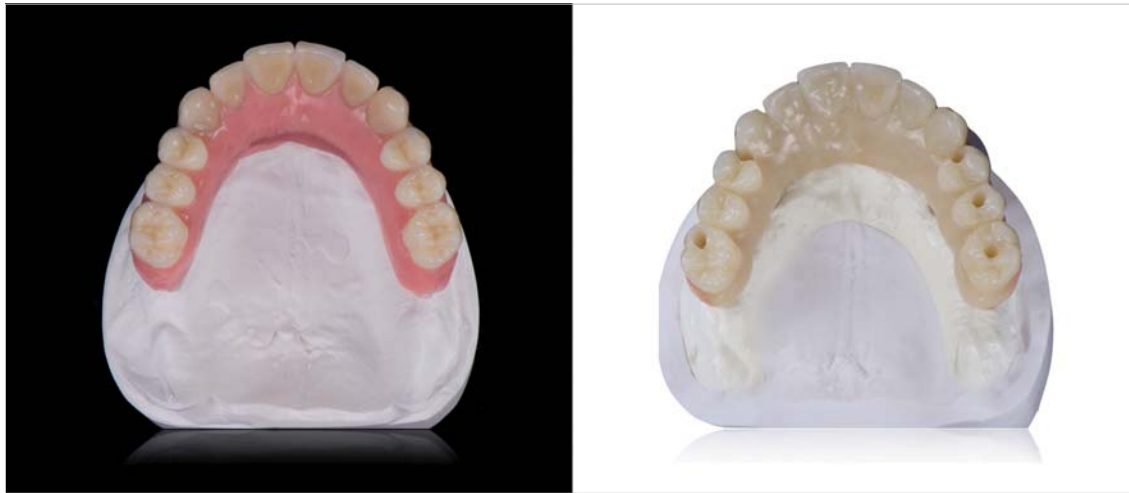*Taking the old fixed lower jaw prosthesis into account, we create the new dental restoration in the upper jaw.*



*Side profile view (3D face scan) with CBCT data record.*

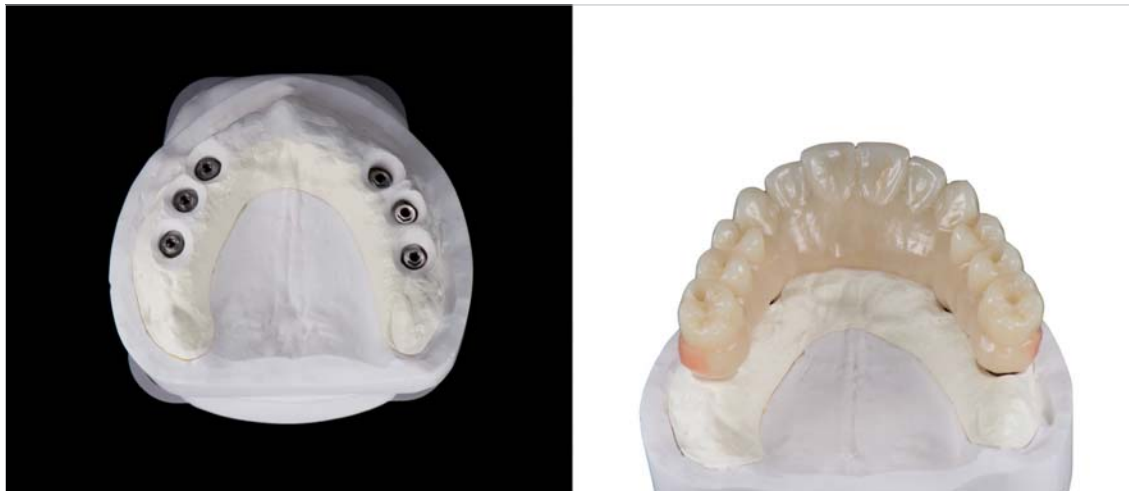

*This profile view shows the diagnostic set-up (white teeth). This is the basis for the production of the therapeutic prototype.*

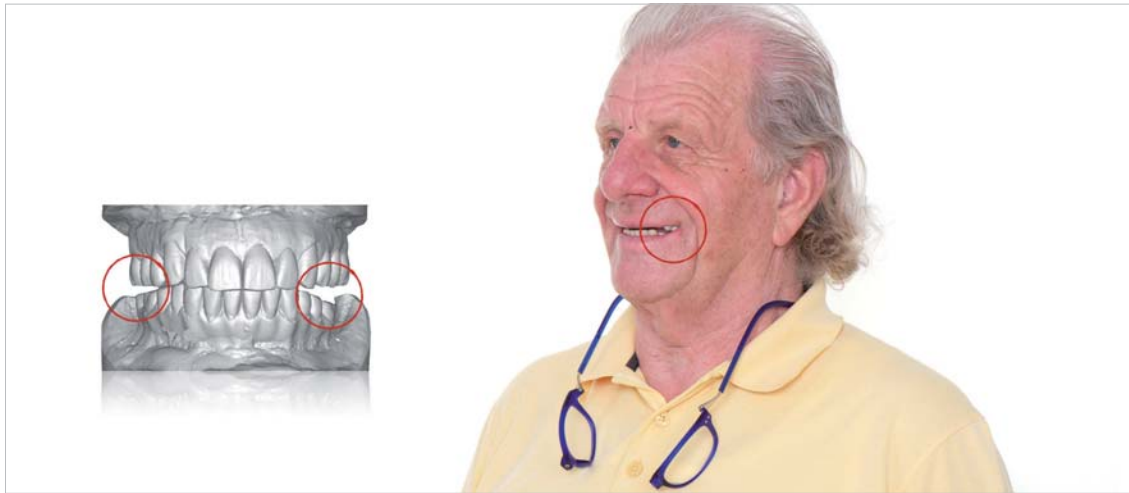

**PROTOTYPE: MAXILLA**

*Based on the digitised set-up, the prototype is monolithically milled from tooth-coloured resin and veneered with gingival masses.*

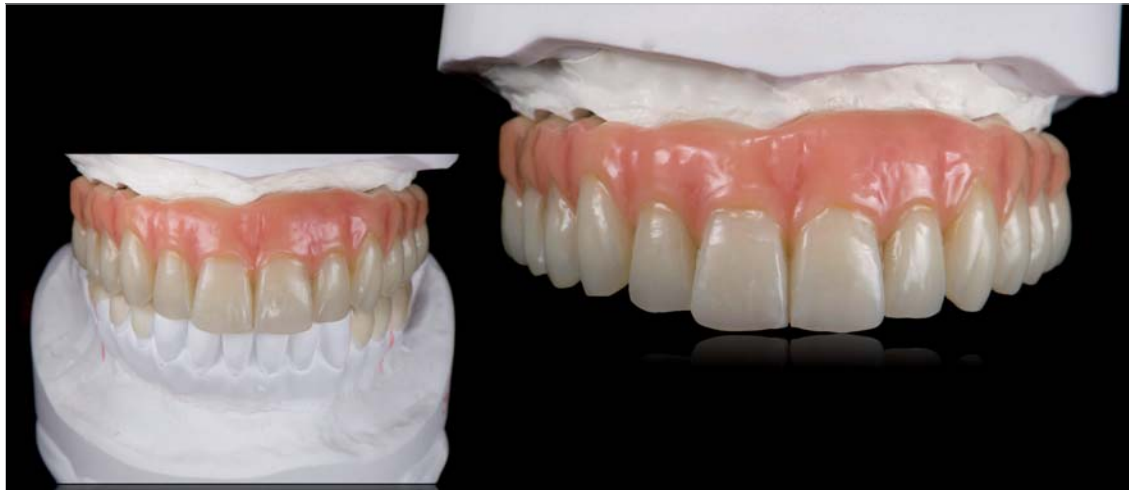

*The prototype is screwed occlusally onto the six implants in the mouth.*



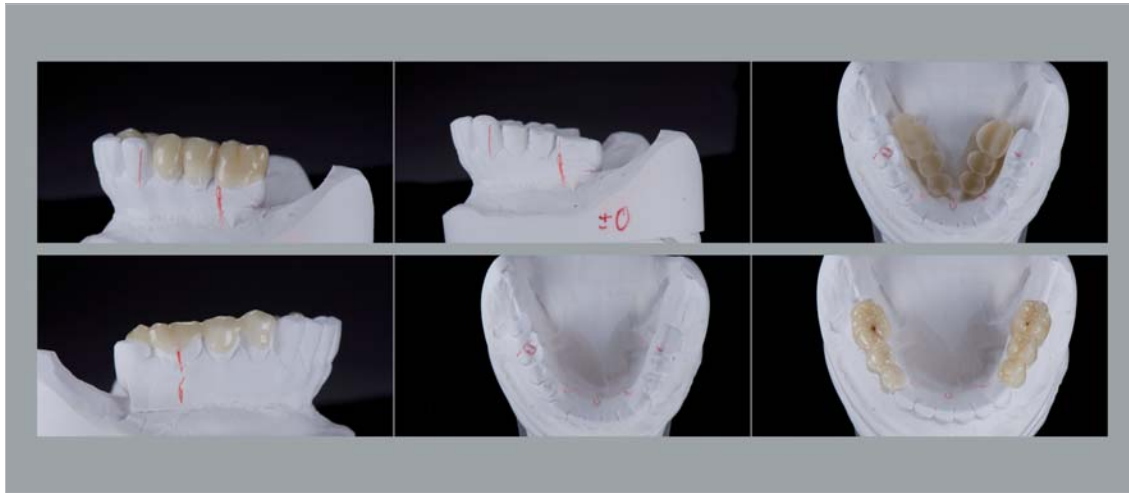
## OCCLUSAL PLANE LOWER JAW?

*The therapeutic prototype in the maxilla corresponds to the physiological occlusal plane. Clearly visible: the denture in the lower jaw must be increased in the molar area.*

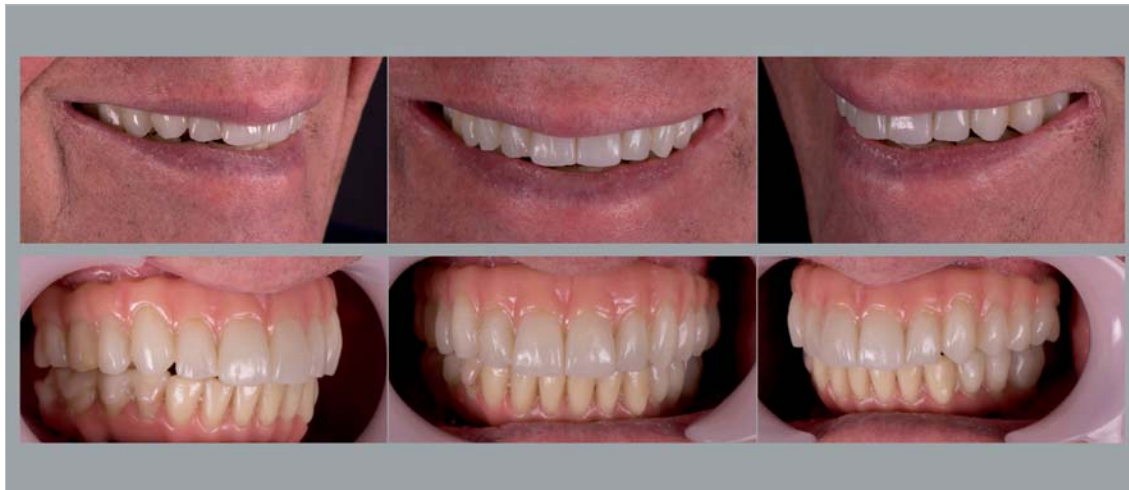

*Matching the therapeutic prototype in the upper jaw, resin table-tops are manufactured for the posterior teeth in the lower jaw.*

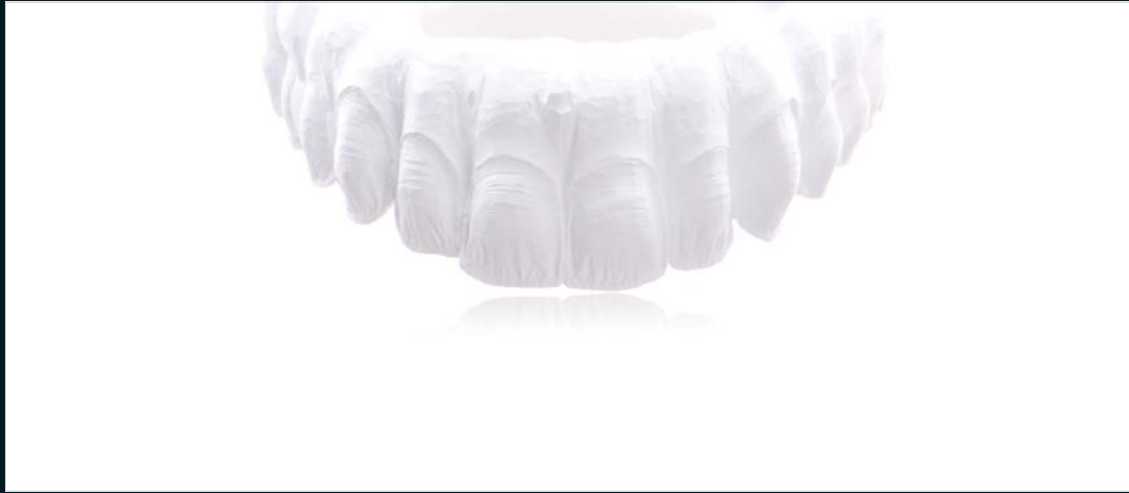



*Table-tops on the model: they are glued in the mouth onto the existing dental prosthesis in the lower jaw. Thus, the occlusal plane is compensated towards the direction of the maxilla.*



*The clinical situation with therapeutic prototype in the maxilla and table-tops in the mandible. The patient tests wearing comfort, hygiene, functional conditions, speech motor skills and aesthetics for about six months.*

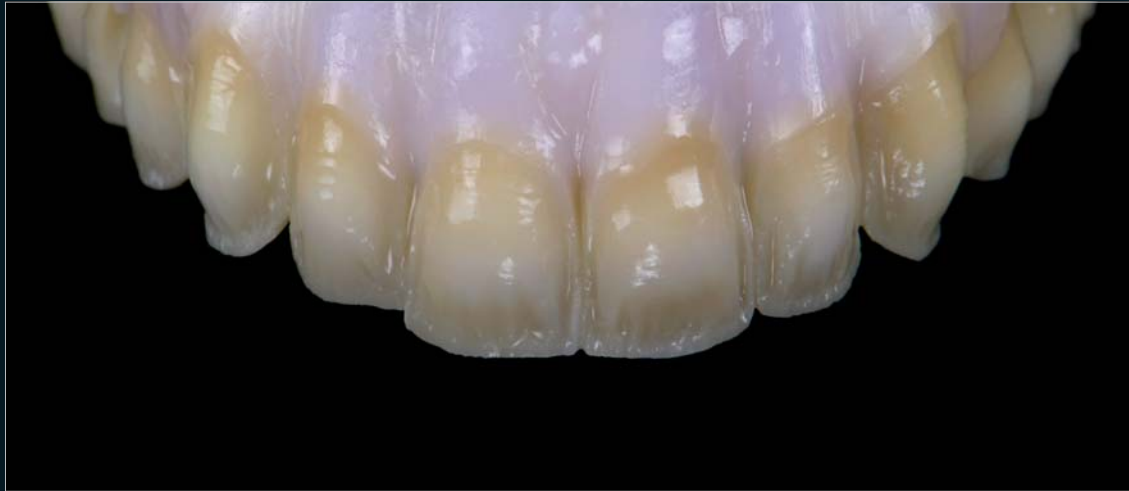

## FABRICATION OF THE FINAL RESTORATION

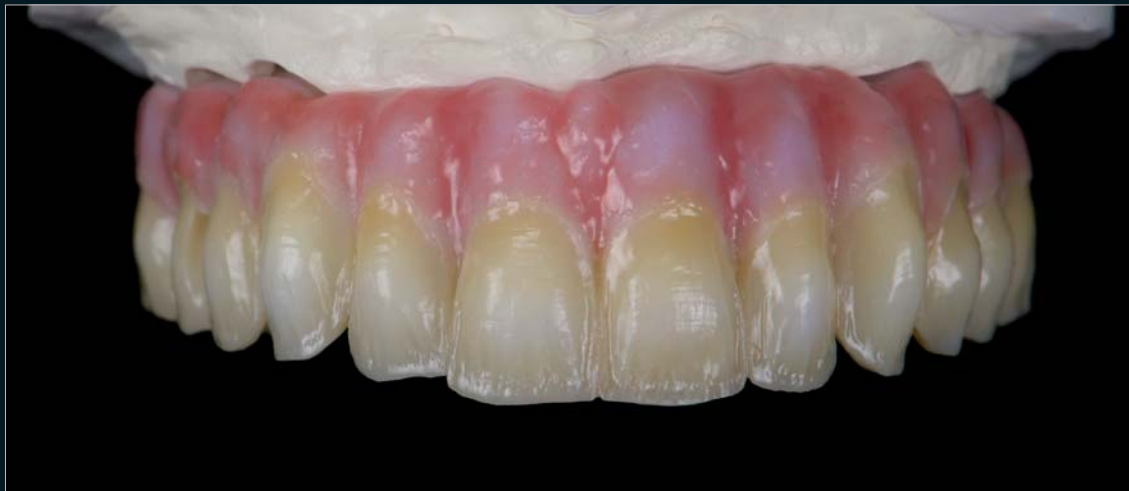*After the test phase, the framework for the fixed restoration in the maxilla is designed on the basis of the available data and milled out of Prettau® zirconia.*



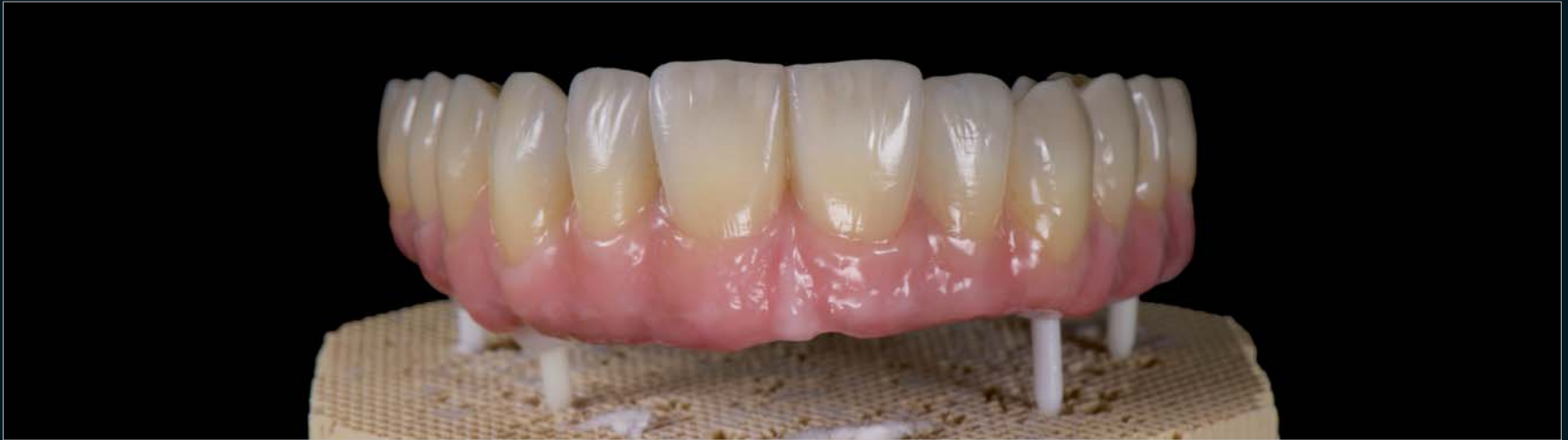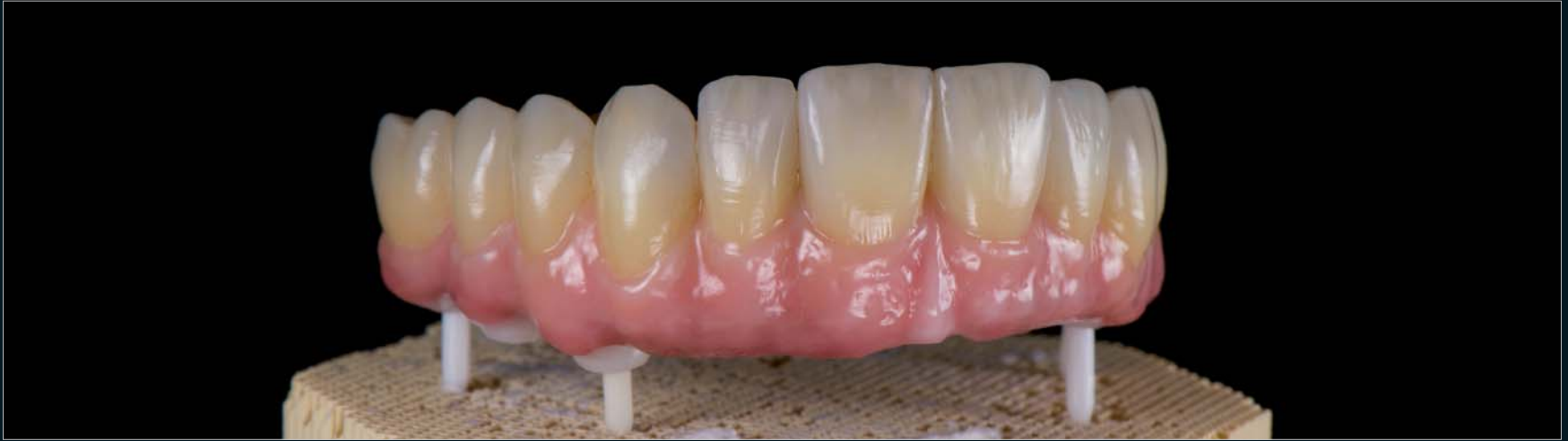*Before sintering, the framework is individually coloured with Colour Liquid Prettau® Aquarell and Intensive colours.*

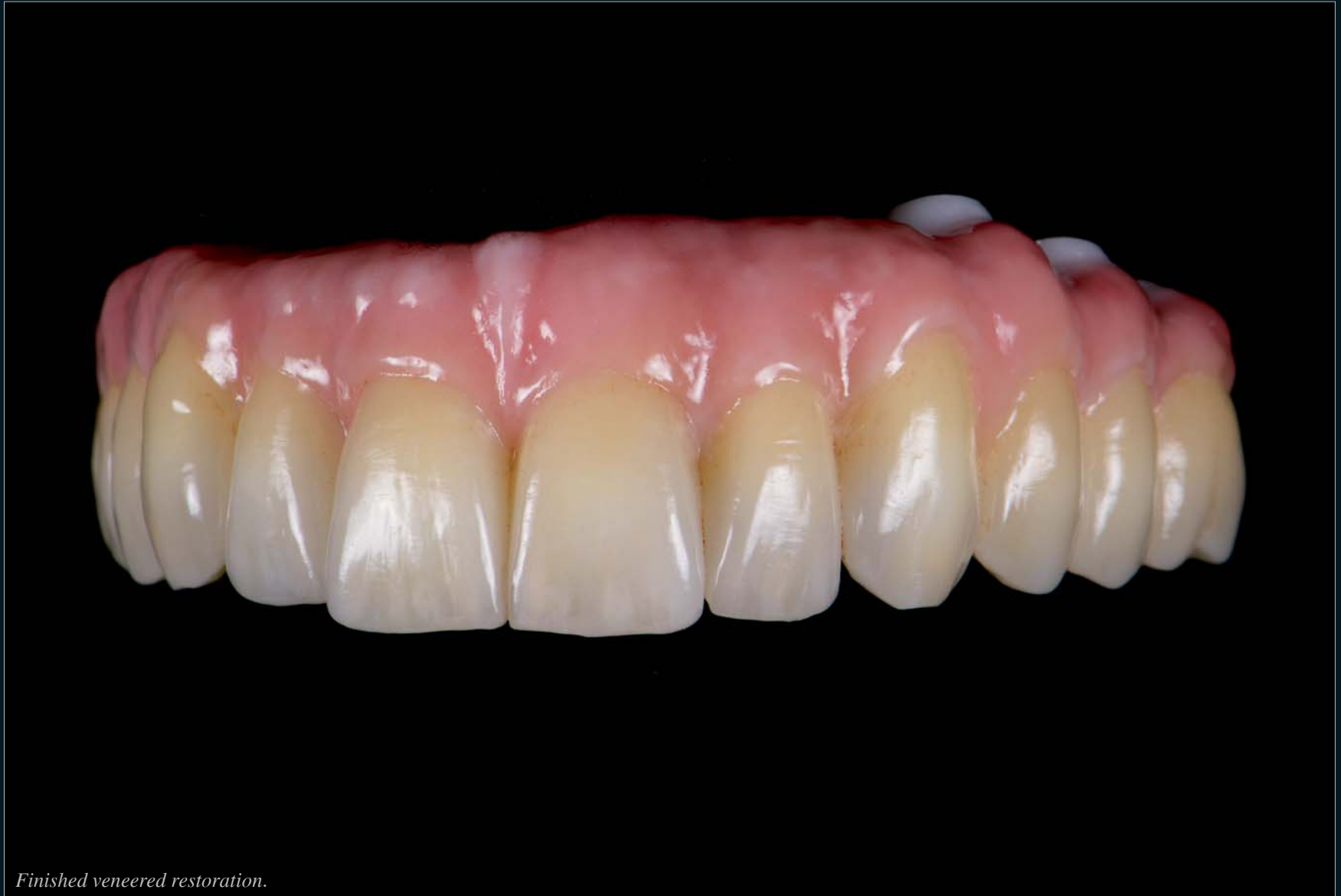

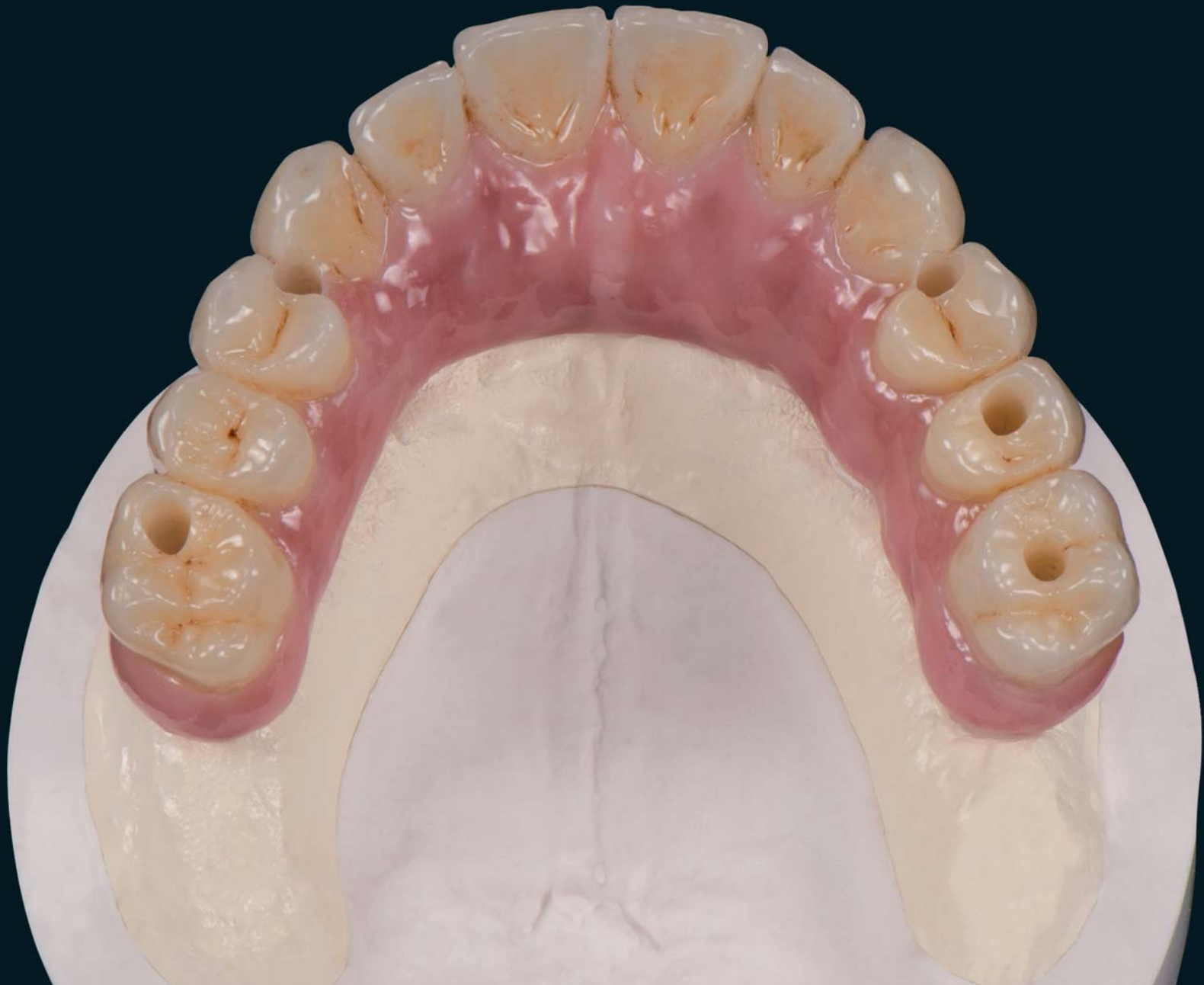*The framework immediately after it was densely sintered as an optimal colouring base.*

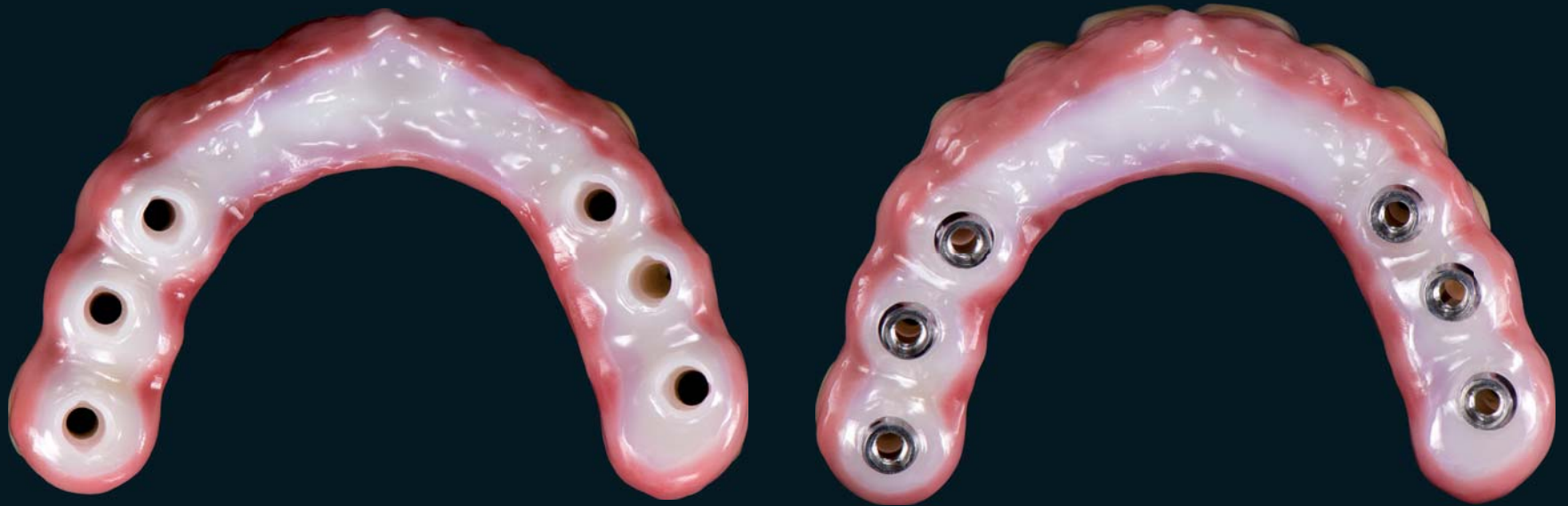

*Ceramic veneering of the vestibular parts; here after the first dentine firing. In the palatal and occlusal areas, the framework is monolithically milled.*

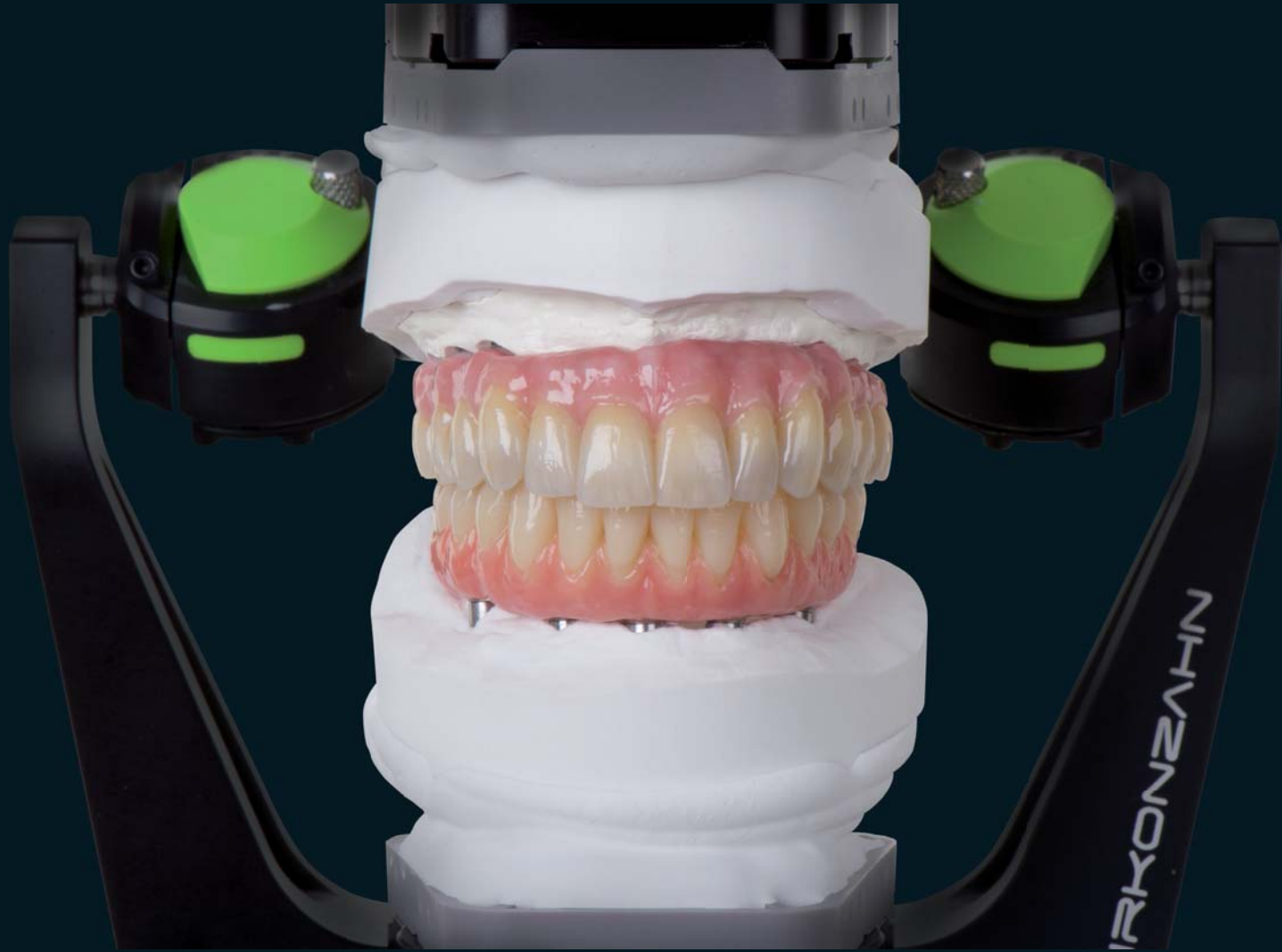




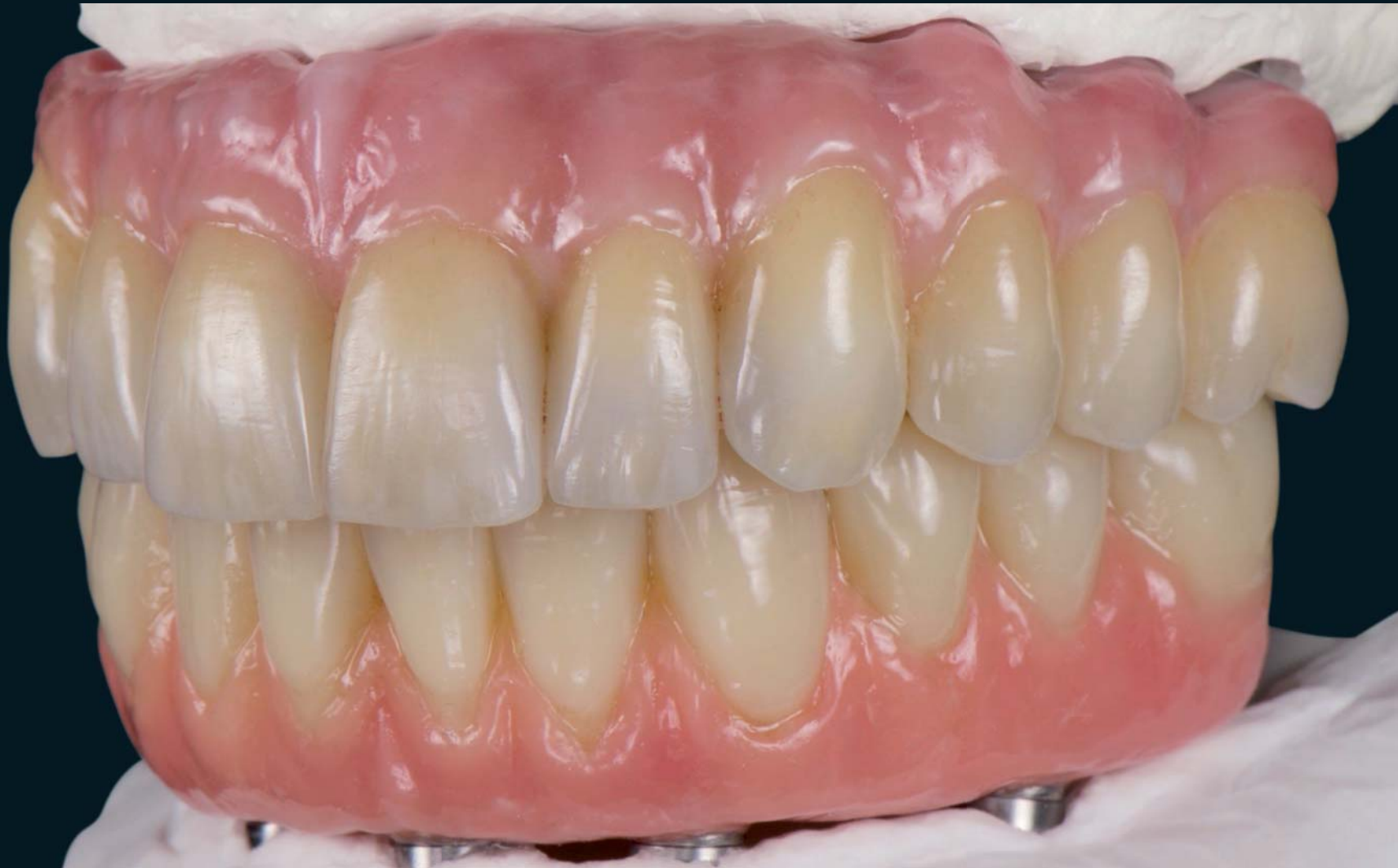


*The finished ceramic restoration in the maxilla.*







*At the patient's request, the prosthesis in the lower jaw has later been entirely renewed. The existing titanium framework is newly veneered with composite to achieve the correct plane.*



*The patient has a certain resemblance to Jean-Paul Belmondo. The aesthetic design of the dental restoration was also based on the actor.*





**Zirkonzahn®**



## PLANESYSTEM®

*Zirkonzahn Worldwide – Via An der Ahr 7 – 39030 Gais/South Tyrol  
T +39 0474 066 680 – F +39 0474 066 661 – [www.zirkonzahn.com](http://www.zirkonzahn.com) – [info@zirkonzahn.com](mailto:info@zirkonzahn.com)*

ENGLISH



WEAB8109EN=

*All information is subject to change. Errors and omissions excepted. Version: 06/03/2019*