

Zirkonzahn®

Human Zirconium Technology

PLANESYSTEM®

Analysis, capturing and transfer of referenceable individual patient information

Enrico Steger, MDT



WHEN IT COMES TO HEALING ...

... only the best is good enough. For this reason, we decided to work with my long-time colleague, Udo Plaster, MDT, in the realm of patient and model analysis.

His PlaneSystem® is a transfer method that respects and recognises the patient as a person. Whether we choose the digital or the traditional route in the preparation of dental restorations, the accurate and individual recording of patient data by the PlaneSystem® will pave the way for the pursuit of complete health. We have integrated the PlaneSystem® to 100% into our Zirkonzahn workflow and are constantly working with Udo on new ideas and improvements.

Udo Plaster, MDT



PREFACE

Each person brings with his/her individual situation specific requirements into the dental practice. As with a compass, the individual circumstances also determine the solution approach, e.g. within the framework of a complete prosthetic restoration. The digital technologies offer us fascinating possibilities. The entire patient situation can be measured and validated using defined values. This reproducibility offers a high degree of safety for complex therapies.

PRESENTATION OF THE PATIENT CASE

The prosthetic rehabilitation of a patient who has been suffering from severe physical complaints for years is presented here. Based on a dental diagnosis and a dental technical analysis, the reason for the health problems could be identified in close cooperation with the physiotherapist: her dysfunctional dental restoration. After a detailed situation analysis, the determination of patient-specific reference planes with the PlaneSystem® (Zirkonzahn) and anatomical orientation points, the patient received a therapeutic prototype with a newly defined position. This led to freedom from complaints and was the basis for the further therapeutic steps. These included implant planning, a second prototype with sufficient wearing time and a final, long-lasting and very aesthetic restoration for the patient, that relieved her of the physical complaints.

Such functional problems can only be solved by a close cooperation between dentist and dental technician. For us, digital technologies have become indispensable. The clinical information from the patient's mouth can be synchronised 1:1 with the dental technical workstation. The information can be transferred from the analogue to the digital world and vice versa – without losing any information!

Dr. Siegfried Marquardt, Udo Plaster, MDT

Dr. Siegfried Marquardt





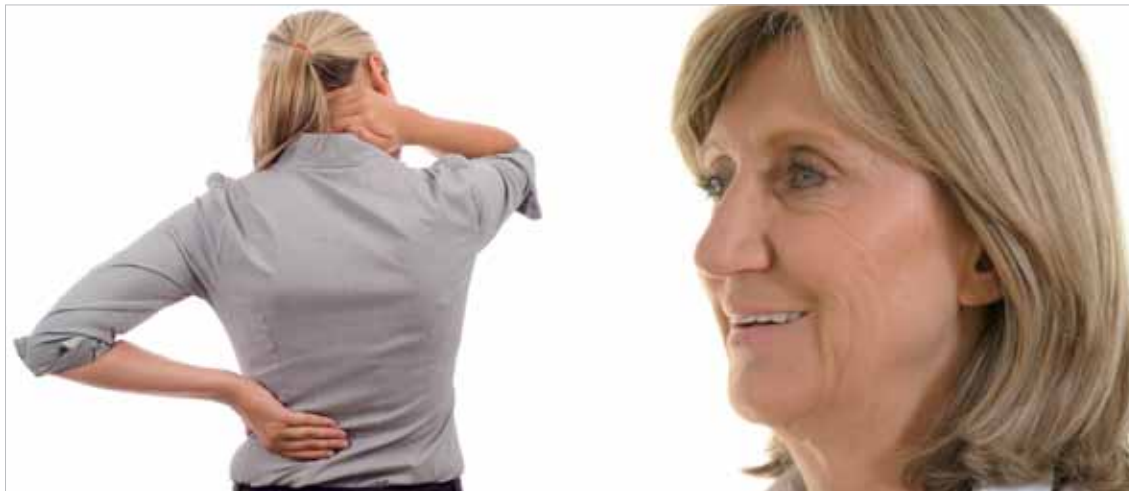THE PATIENT:

“I’VE BEEN SUFFERING FROM HEADACHES AND STRONG TENSIONS IN THE NECK AREA FOR A LONG TIME. THIS SITUATION RESTRICTS ME VERY MUCH IN THE SOCIAL EVERYDAY LIFE. I’M JUST FEELING UNCOMFORTABLE AND FINALLY WANT SOME RELIEF FROM THE DISCOMFORT.”



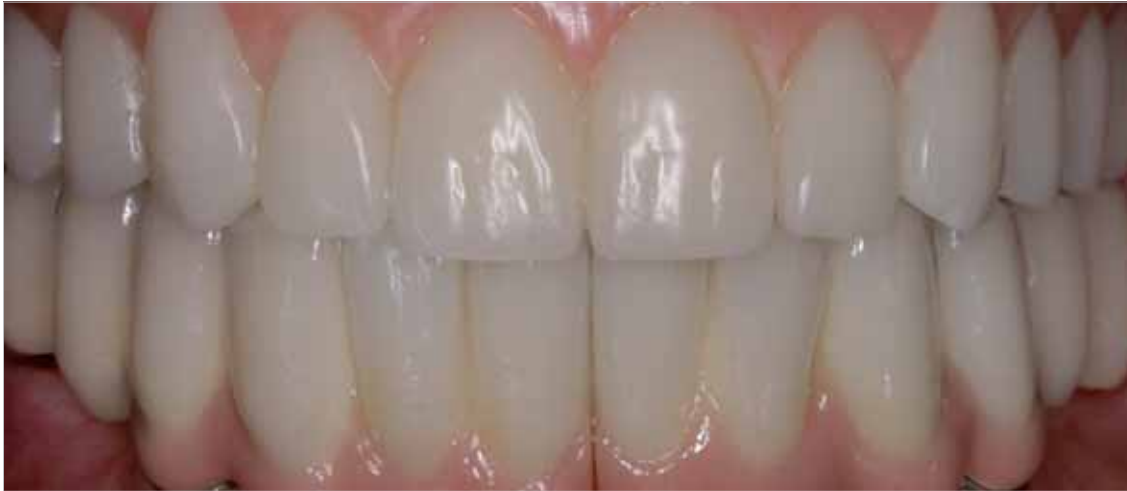OVERVIEW OF THE COURSE OF TREATMENT

1. *Analysis & diagnostics*
2. *Prototype 1 (maxilla), table-tops (mandible) and first therapeutic phase*
3. *Planning of the dental restoration and implantation*
4. *Prototype 2 (long-term provisional in the maxilla) and second therapeutic phase*
5. *Prototype (lower jaw)*
6. *Fabrication of the final prostheses*

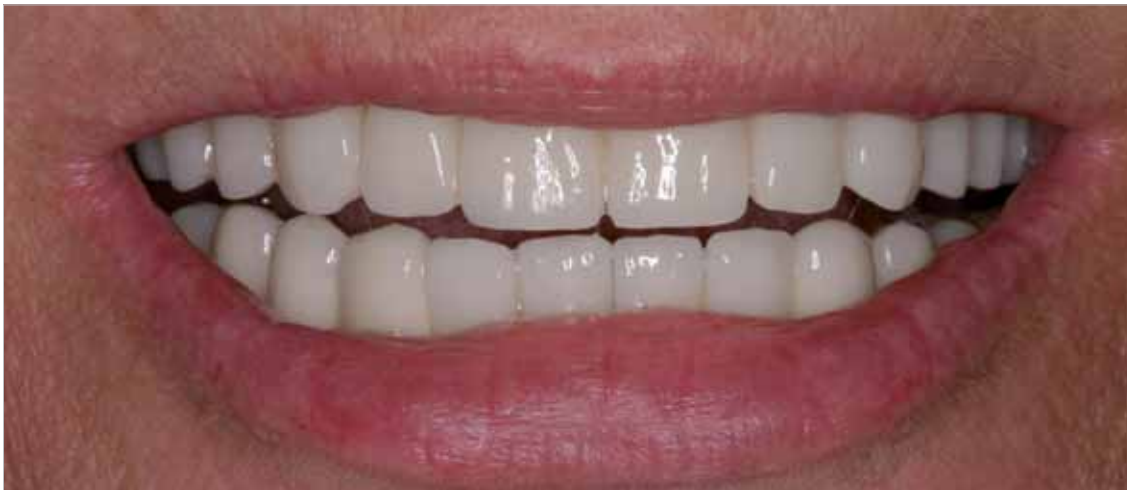

2006 – 2013: SEVEN YEARS OF WHOLE-BODY DISCOMFORT

The patient has been suffering for years from severe tension in the neck area and chronic headaches. Physiotherapeutic treatments were not successful.

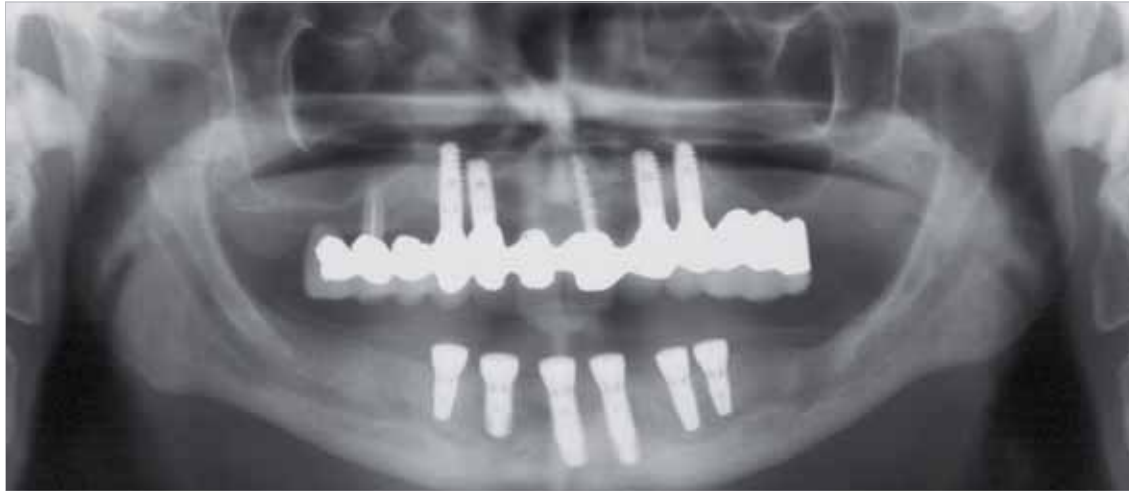

The change of her physiotherapist in 2013 “got the ball rolling”. Dysfunctional dentures are suspected to be the cause of the complaints. In coordination with the physiotherapist, the dentist and the dental technician, a comprehensive diagnostics has been carried out.



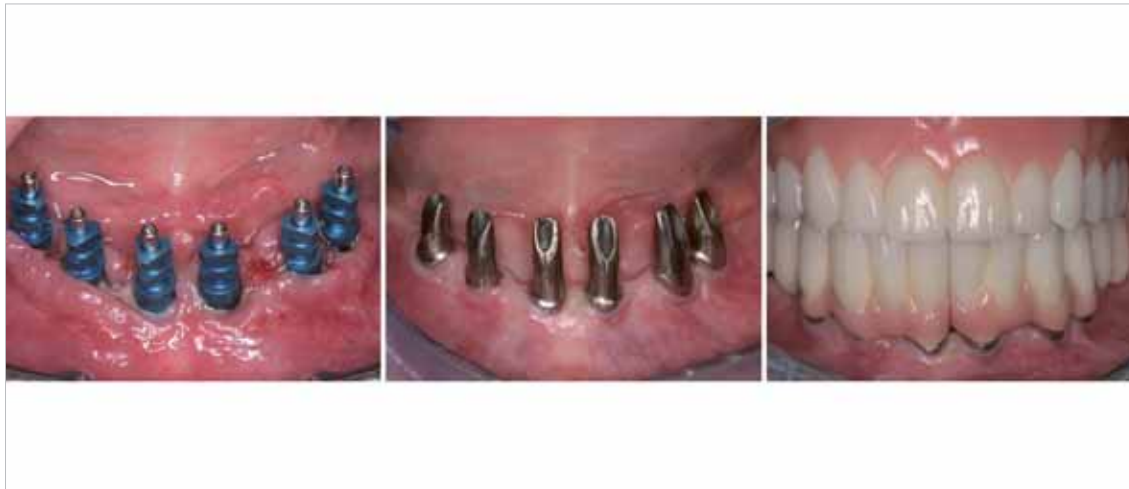FIRST DENTAL TECHNICAL ANALYSIS (2013)

- *Conversation regarding the dental history*
- *Analysis of the face and the model*
- *Checking the speech motor skills*
- *Analysis of the existing dental restoration*



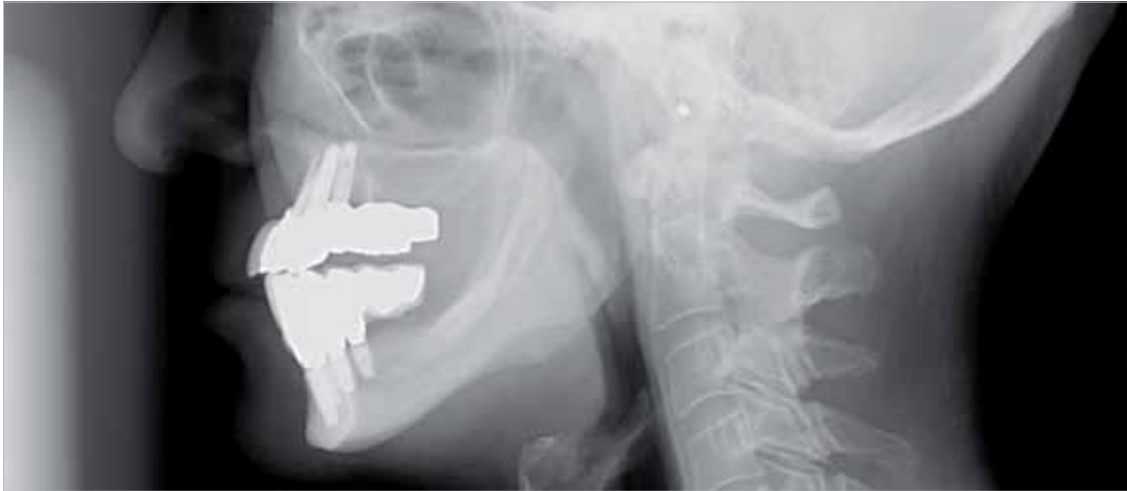DENTAL HISTORY (YEAR 2006)

The patient is provided with a removable telescopic work in the maxilla. Four implants, a screw (21) and a root-treated tooth (15) are visible in the upper jaw. Six implants (SPT® Element, Thommen Medical) are inserted and healed in in the lower jaw.



After creating an implant impression, the dental technician at the time fabricated individual abutments (at the same time primary parts) and a double crown prosthesis. The existing restoration in the upper jaw is reworked accordingly.*

** not the author of the brochure*



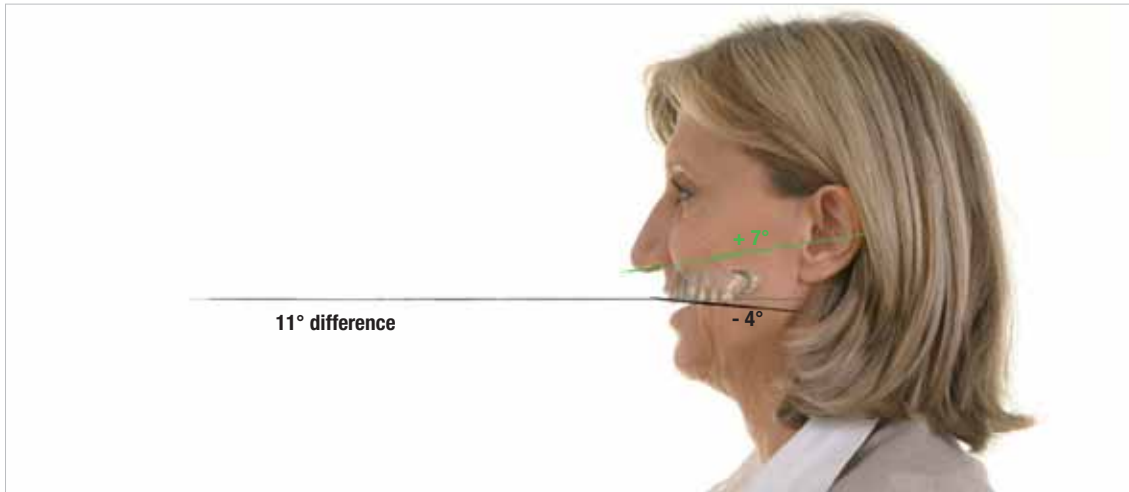
ANALYSIS: CEPHALOGRAM

The lateral cephalogram reveals that the dental restoration is not functionally correct or does not correspond to the patient-specific requirements. There is hardly any occlusal contact in the molar region, but predominantly on the anterior teeth.



ANALYSIS: OCCLUSAL PLANE AND REQUEST OF THE PATIENT

First analysis of the digitised models; the occlusal plane does not correspond to the physiological conditions. To compensate for this, the patient is “pushed” into a physical malposition. In addition to freedom from symptoms, the patient hopes that the new dental prosthesis will also correct the sunken upper lip.



ANALYSIS: ALA-TRAGUS PLANE

To what extent does the occlusal plane of the denture deviate from the physiological situation?

The answer results from a measurement for which a zero line serves as reference.

The patient positions herself in the Natural Head Position. The image from a lateral view with the situation model shown (maxilla) illustrates the deviation between the ala-tragus line (green) and the current occlusal plane (black).*

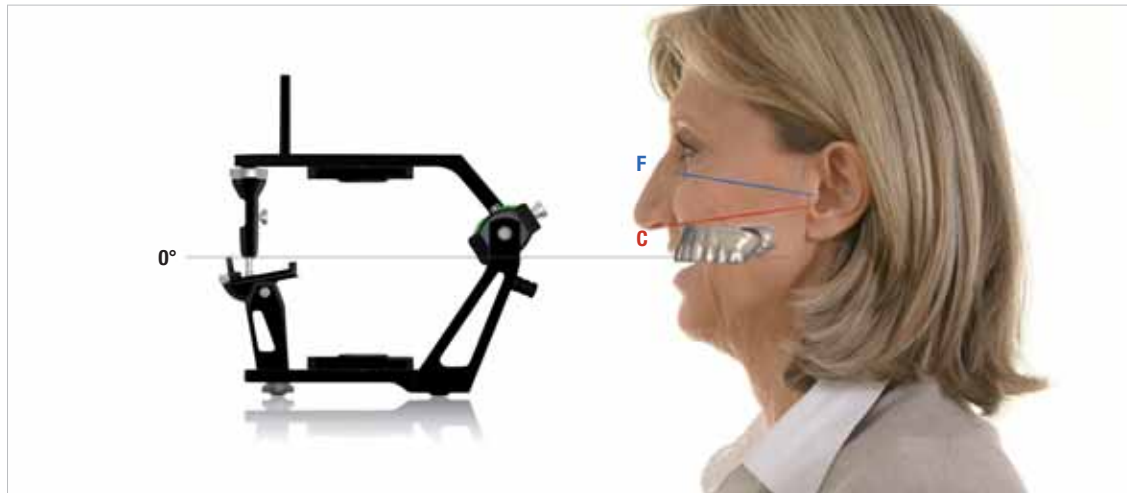
The difference is 11° .

**Ala-tragus line = connecting line from the ala nasi (ala of the nose) to the tragus (entrance of external auditory canal)*



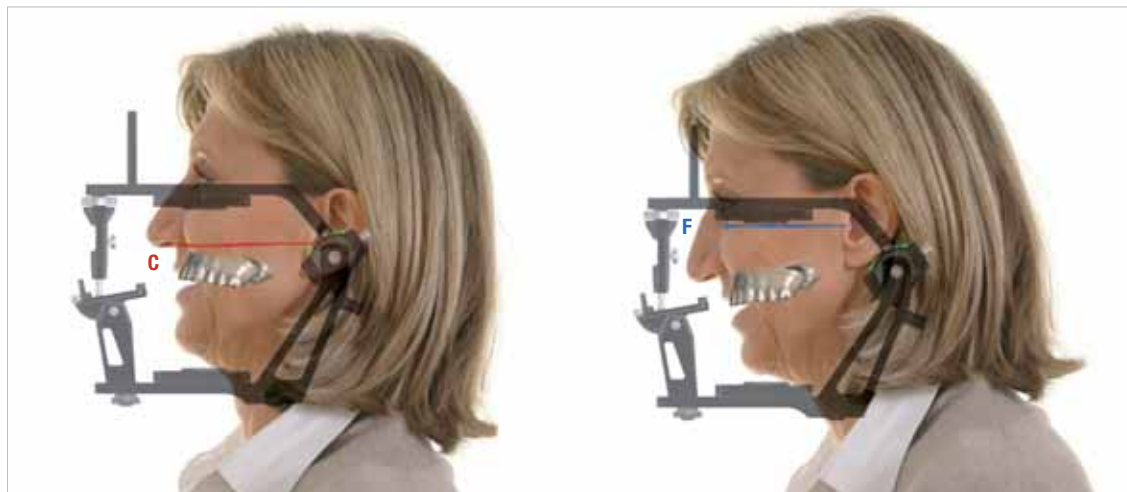
INFORMATION GAP BY MEANS OF FACEBOW ANALYSIS

For the production of the dental restoration in 2006, the models were transferred to the articulator with the help of a face bow.



ANALYSIS: EXISTING DENTAL RESTORATION

Reference on the skull for the fabrication of the dental restoration (2006) at that time was the Frankfurt Plane (blue line) as an arbitrary axis. The dental technician therefore lacked important information for the patient-specific reproduction of the planes. This could have been the reason for the incorrectly interpreted occlusal plane.



REALISTIC REFERENCE?

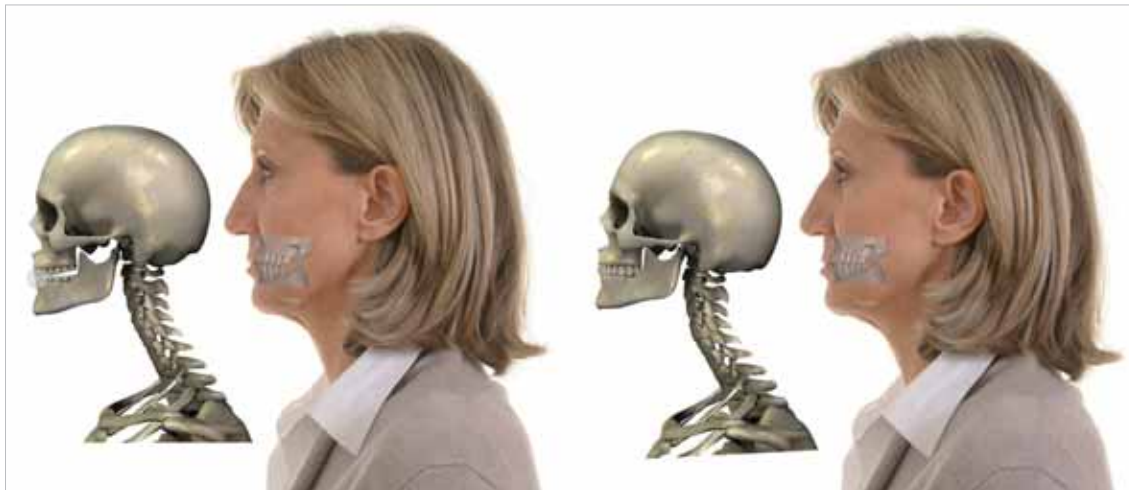Although the positioning of the occlusal plane in relation to the Frankfurt plane in the articulator appears to be good, the realistic situation reveals a different picture. Note: Working with skull-related references, rather than skull-specific references, makes the communication between dentist and dental technician difficult. The situation from the mouth/skull is not identical with the situation in the lab articulator.



ANALYSIS: NATURAL HEAD POSITION (NHP)*

The NHP assesses craniofacial growth, the position of the restoration in the skull and the speaking distance. The patient's statement that her tongue is constricted when speaking and causes unwanted hissing sounds is confirmed.

**NHP = the natural position (without exogenous influences) where the patient is in equilibrium and looks himself/herself in the eyes in a mirror.*



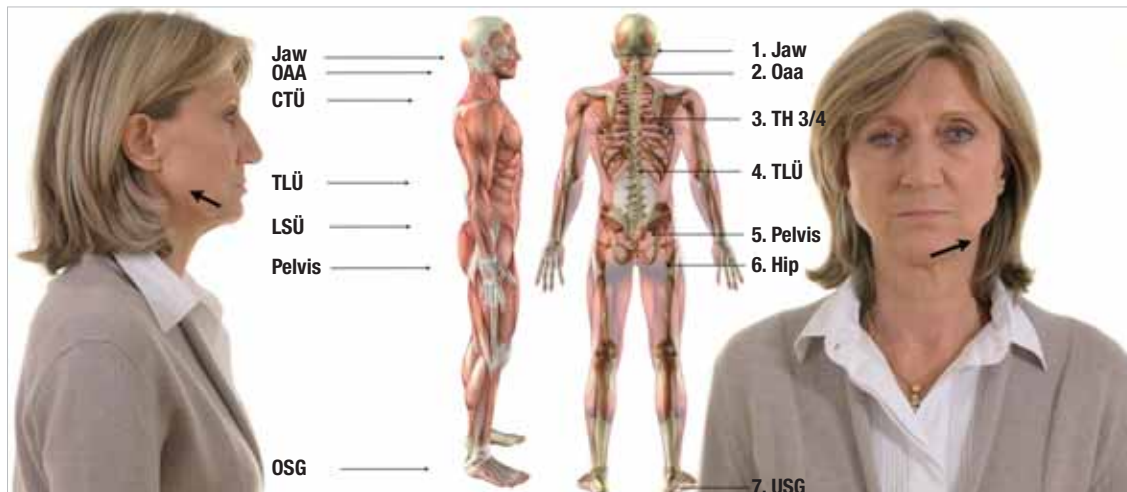
ANALYSIS: HEAD POSTURE

When testing the speech motor skills, the sagittal view shows that the patient pushes her head forward when speaking (head forward position) and "subsides" backwards when biting.



ANALYSIS: CRANIOFACIAL GROWTH

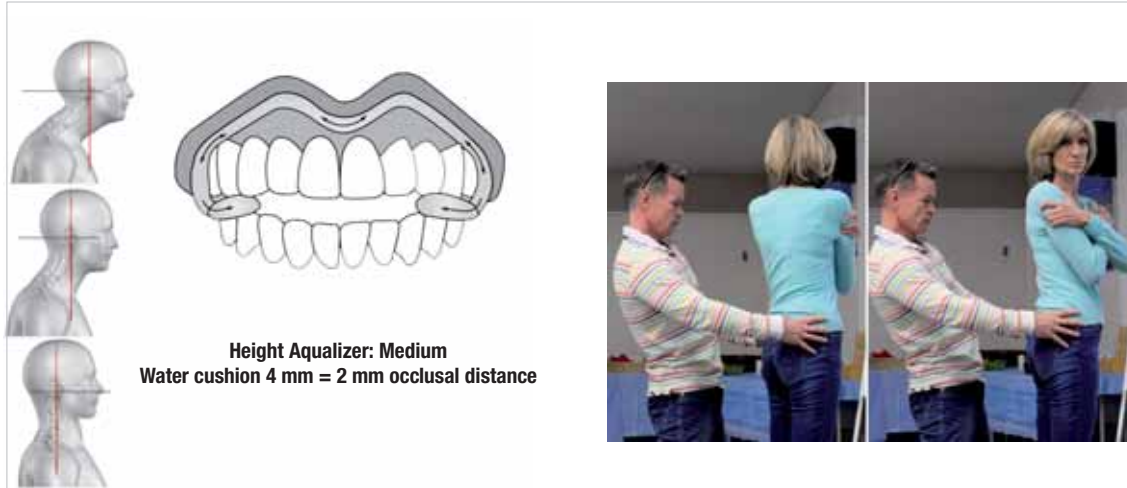Every person has a strong and a weak side of the face; a normal asymmetry that must be taken into account when creating a dental restoration. In this case, the frontal view also makes it clear that the patient “subsides” when biting. The lower jaw not only balances the height vertically, but also shifts to the left.



BACKGROUND INFORMATION PHYSIOTHERAPY: SEVEN COMPENSATION POINTS

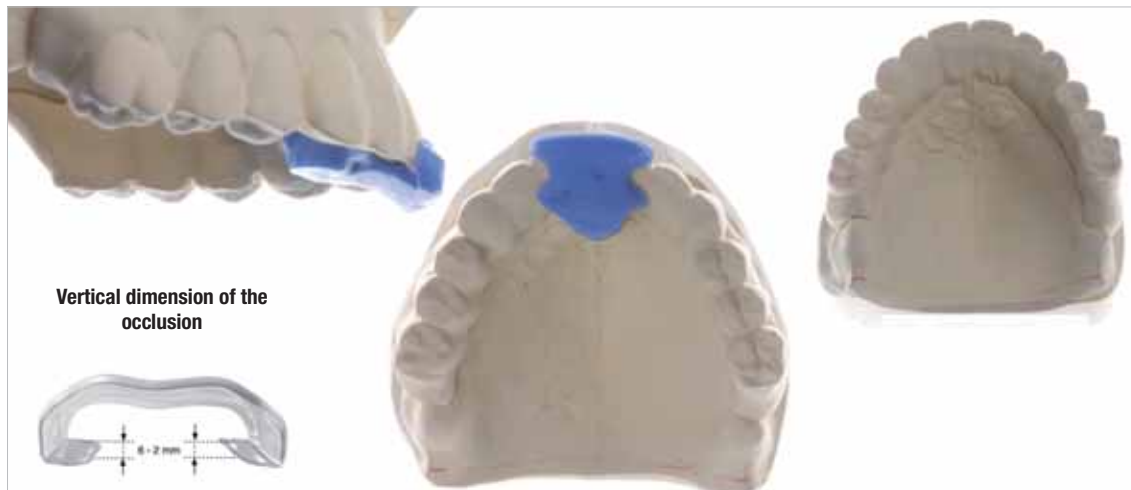
The body compensates for deviations in the orofacial system (e.g. due to dysfunctional dentures). This analysis is done by the physiotherapist. Seven compensation points (Hergenröther, 2015) can be defined on the skeleton:

- from lateral: for the forward head posture or the backward head posture
- from frontal: for the rotation



AQUALIZER*: NEUTRALISATION

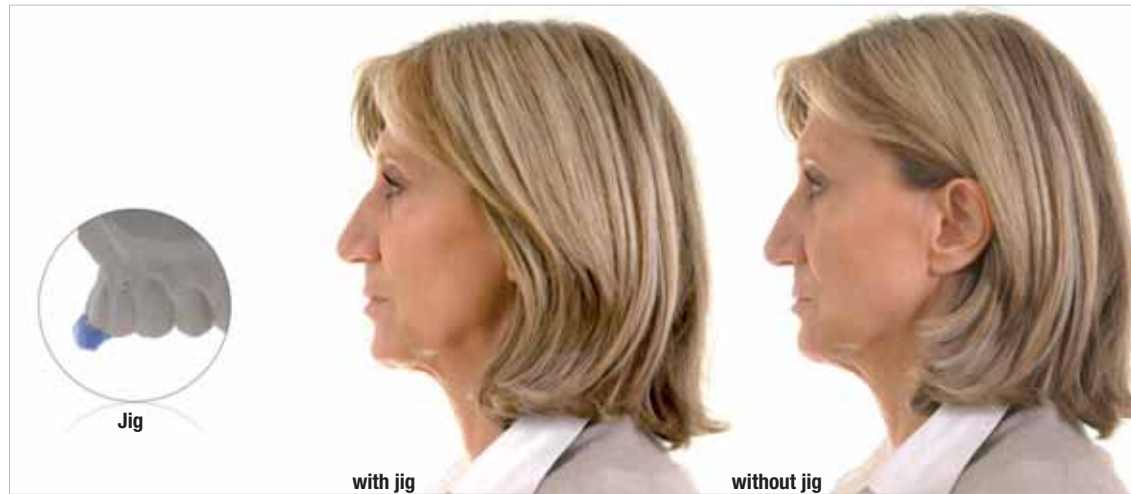Based on the analysis, it is confirmed that: the existing denture is insufficient in the vertical direction. For a new restoration, the vertical dimension (VDO) must be created. A water cushion is used to balance the lower jaw position. The height of the cushion results from the speaking distance and the information of the model analysis. In this case a medium-sized pillow is chosen. After inserting the Aqualizer, the patient finds a comfortable, pain-free position and corrects the height on her own (neutralisation).*



ANTERIOR TOOTH JIG

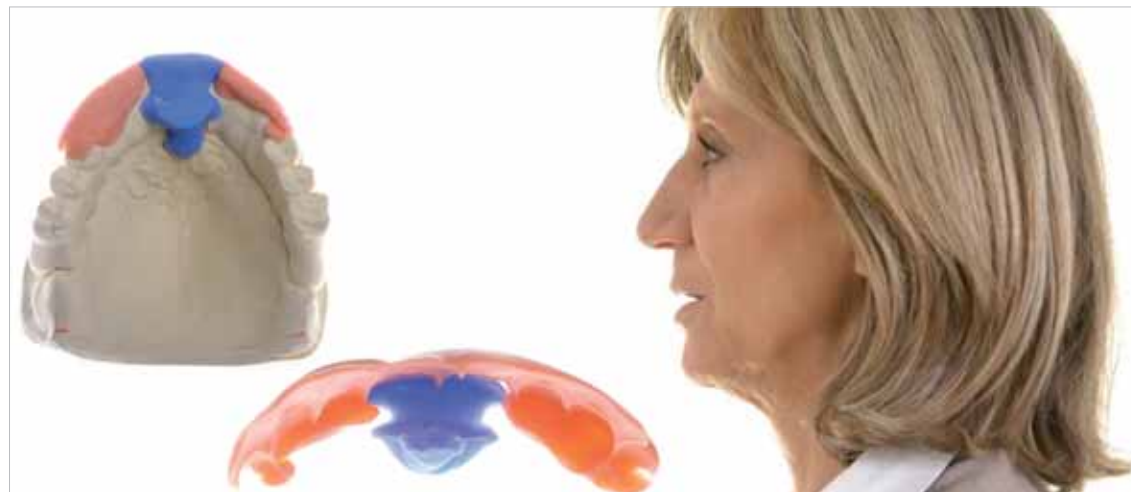After neutralisation with the Aqualizer, an anterior jig at the correct height is made with registration material. After the jig has been elaborated, a point-shaped central lower incisal contact point remains. The extension to the middle of the skull is marked on the jig.

**Aqualizer: Flexible occlusal aid (different heights) consisting of two cushions filled with liquid. The cushions are connected and "communicate" with each other after interocclusal placement.*



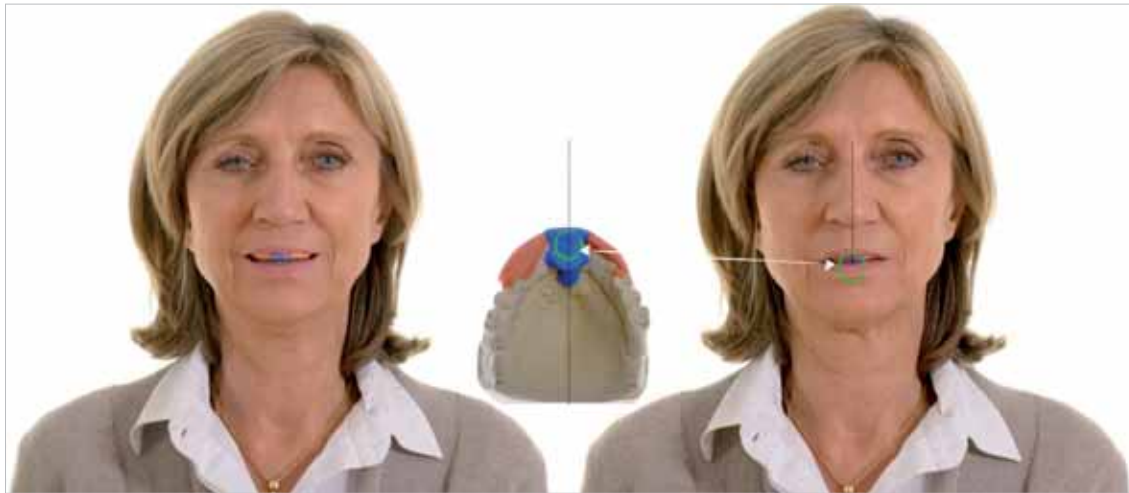
WITH JIG VS. WITHOUT JIG

The anterior jig already normalises the head posture in the physiological area. This is clearly visible on the lip dynamics.

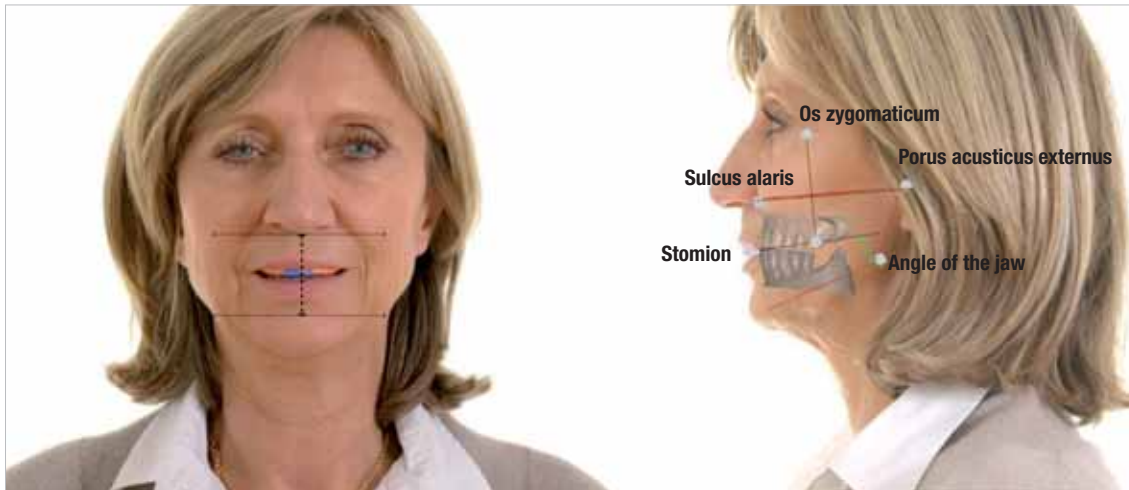


ANALYSIS: DENTAL ARCH


The dental arch of the existing denture is too small and is built up with silicone. At the same time, the upper lip is supported, which also effects the aesthetics.



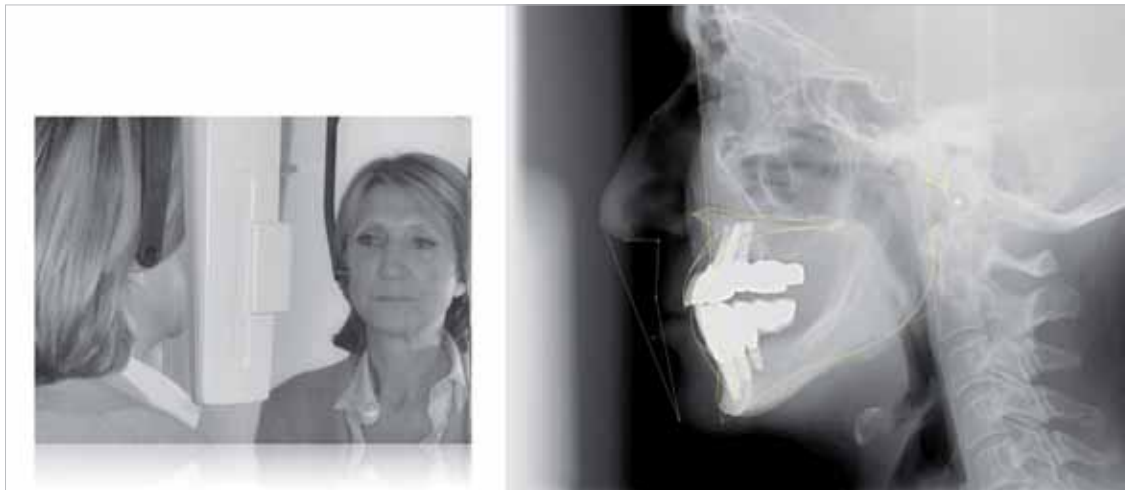The asymmetry of the two halves of the face (right half of the face lower, left half of the face higher) as well as the physiological bite height achieved are clearly visible with anterior tooth jig and the extended dental arch in silicone.



Analysis of the anatomical orientation points referred to as landmarks hereafter (e.g. frenulum superior, frenulum inferior, ala-tragus, jaw angle, os zygomaticum) in relation to the dental restoration in speech motor function. The situation is similar to the diagnostics of the cephalogram, whereby no statements about the musculature can be made with the cephalogram.

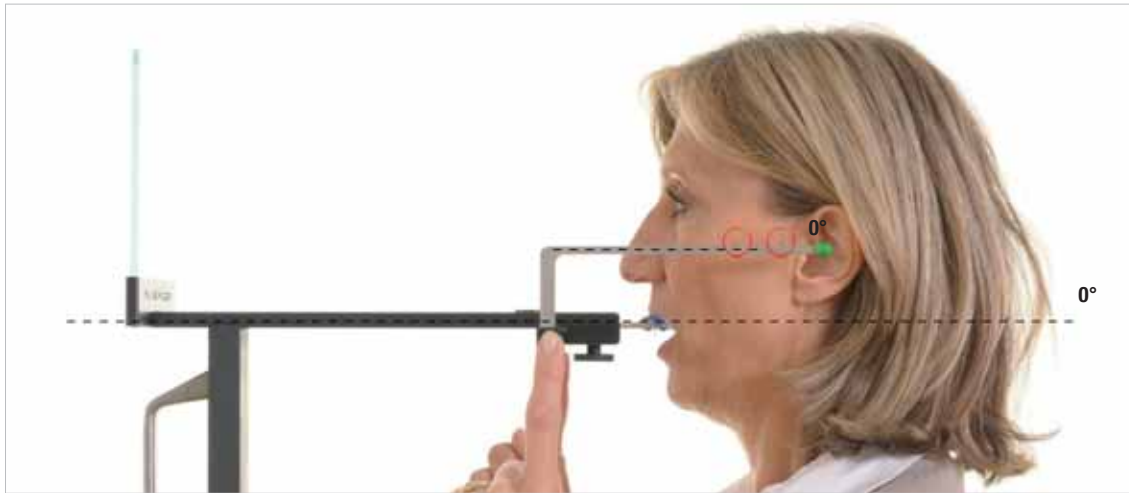


For the articulation of the models, the fixing pin on the articulator is set to 0. The physiological bite height was worked out together with the patient and should not be changed subsequently on the articulator.



*Comparison to the cephalogram
(also recorded in Natural Head Position)*

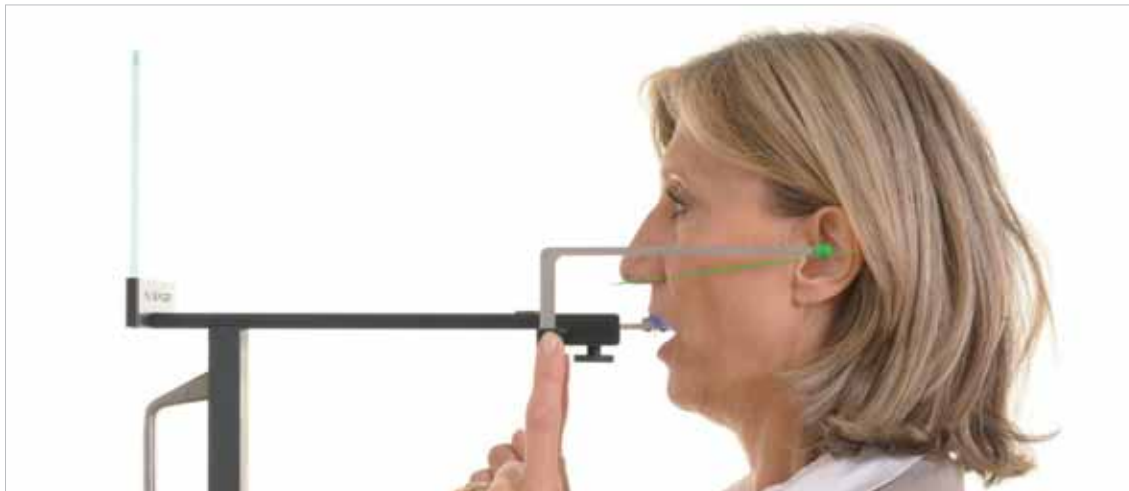
Note: The cephalogram does not allow any conclusions regarding the musculature.



VERIFICATION OF THE REPRODUCIBILITY

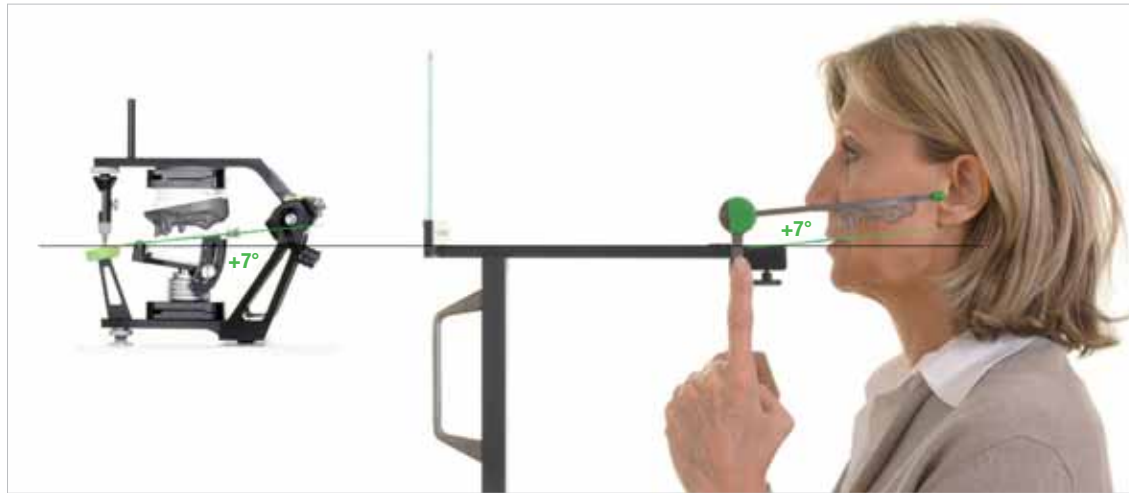
The skull positioning information is transferred to the PlaneFinder® and the Natural Head Position is checked.

**PlaneFinder® version from 2013*



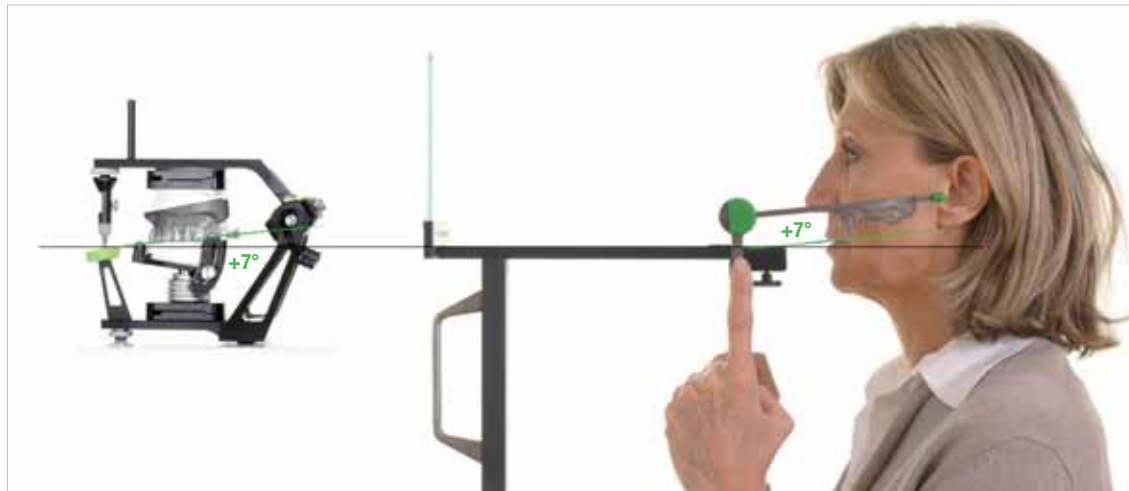
PLANEFINDER®

Reference is again the zero line. The green line (ala-tragus) indicates the plane after which the new dental restoration must be created. An inclination of 7° is validated.

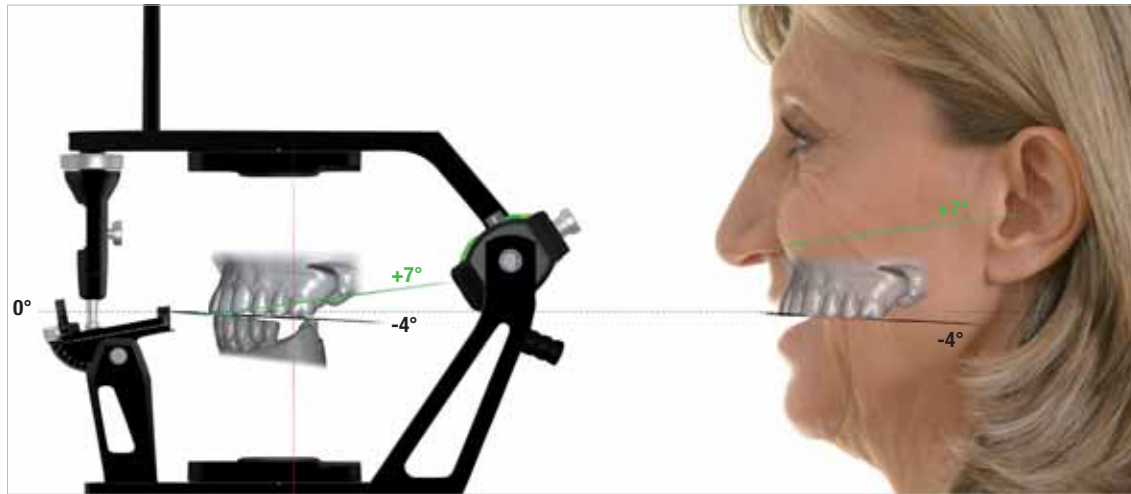


MEASURING ANGLES

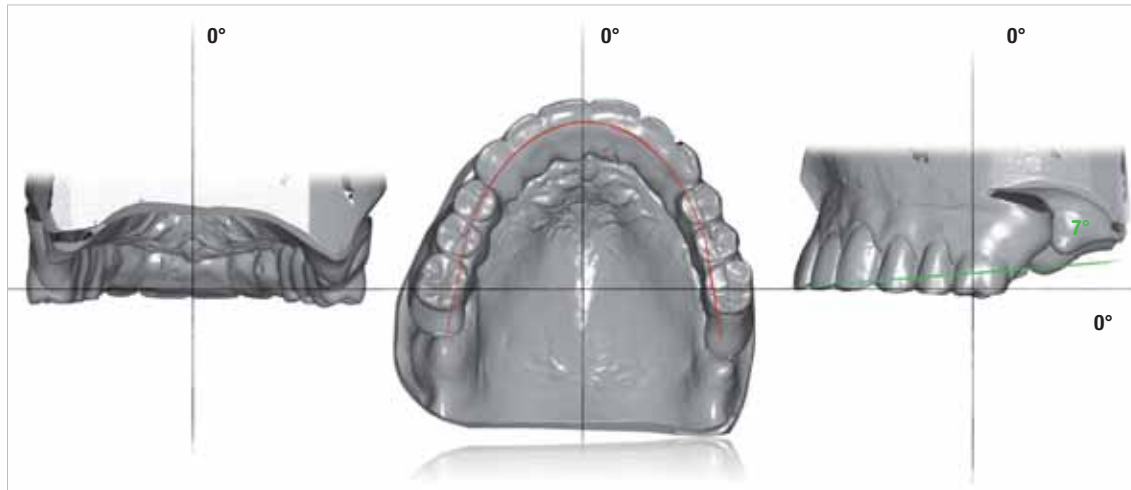
The measuring angles (ala-tragus angle) are equivalent to the worktable on the articulator. Thus, the dental technician now has a 1:1 view of the physiological situation from the patient's mouth.



Situation with inserted restoration in the articulator

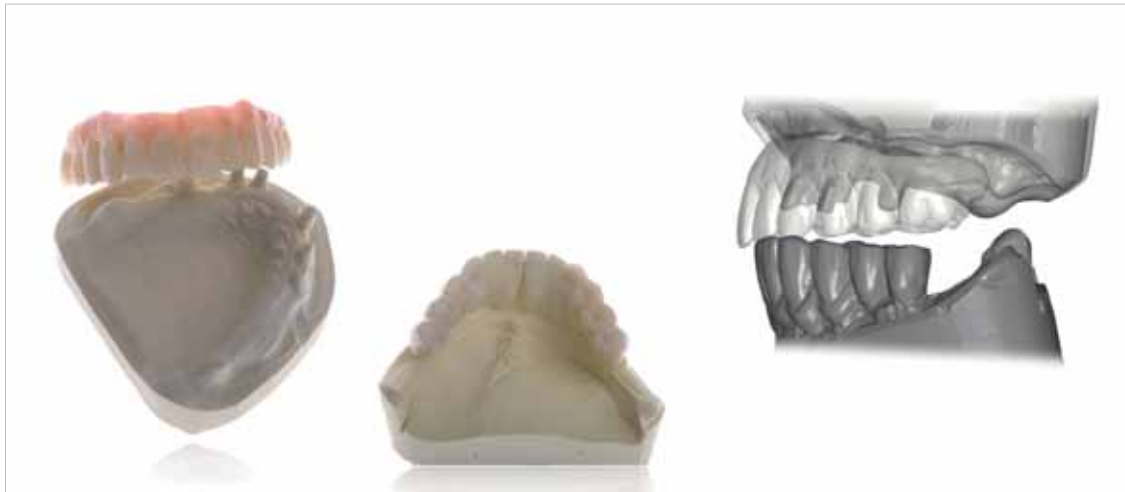

Occlusal line difference: The desired occlusal plane of the planned tooth restoration (green, +7°) deviates significantly by 11° from the occlusal line of the old denture (black line; -4°).



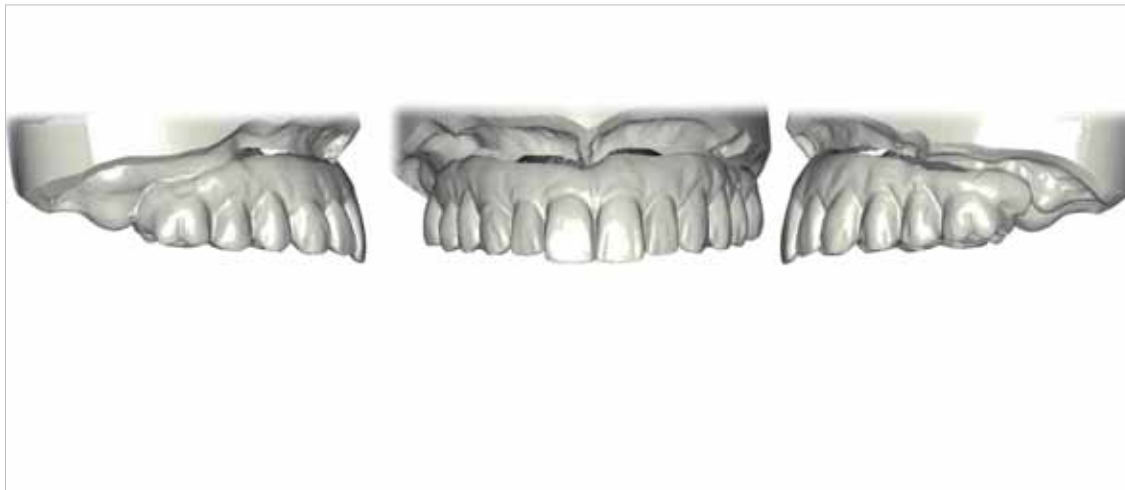Zero lines are reliable and reproducible reference lines that are used to evaluate various parameter, e.g. in the software, including

- *from occlusal (middle): deviations from the dental arch*
- *from lateral (right): deviation of the plane*
- *from palatal (left): comparison left and right side*

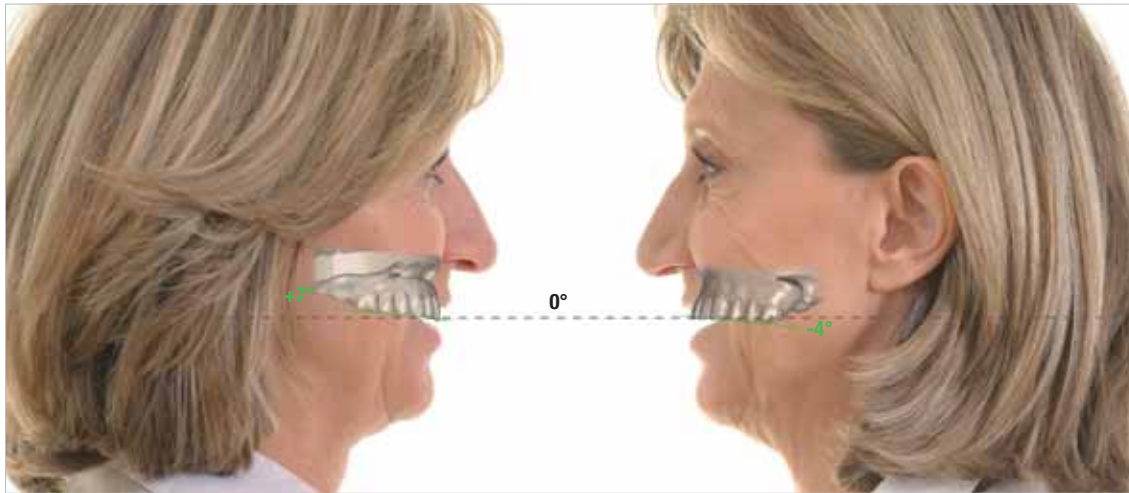


PROTOTYPE 1 – THERAPEUTIC DENTAL PROTOTYPE

When increasing the vertical dimension (VDO), a therapeutic tooth prototype is advisable. The production is based on the information obtained during diagnostics and analysis. Without any invasive measure, a resin restoration for the maxilla is milled from tooth-coloured material (Temp Premium Flexible) and veneered with Gingiva-Composite material. In order to compensate the height in the lower jaw, table-tops are manufactured.



Planned therapeutic prototype of the upper jaw in the software (physiological occlusal height).



The prototype is used to check the desired situation. Over the next few weeks, the patient will assess whether the physical complaints will subside with the inserted prototype. After only a short time, she decides to have the table-tops firmly glued into the lower jaw and to wear exclusively the prototype in the upper jaw.



Clearly visible change: Comparison of the photos with old dental restoration (left) and inserted prototype (right).

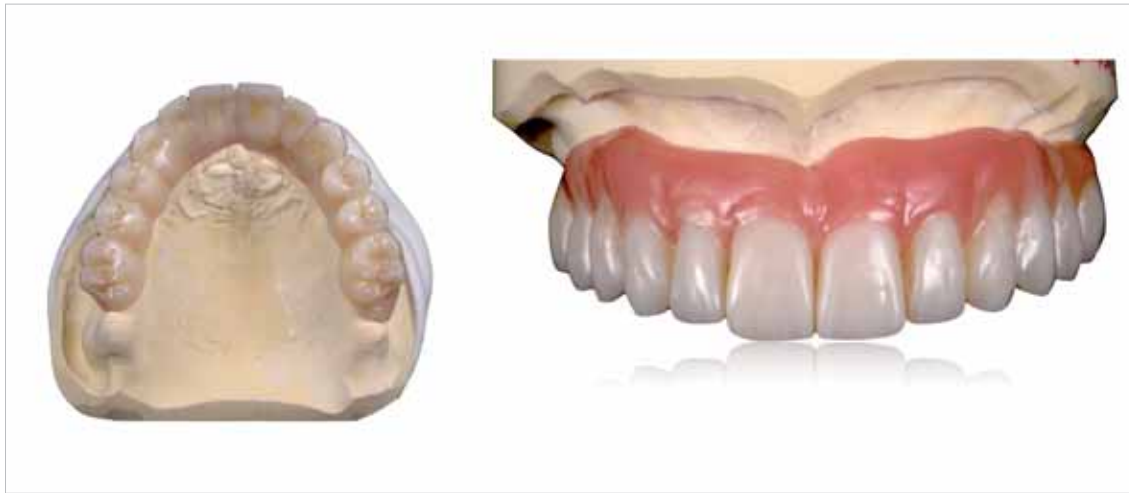

Before (old restoration) – after (therapeutic prototype).

The patient wears the therapeutic prototype for about a year. During this period, the body adjusts to the physiological occlusion again. Not only aesthetically a clear change is perceptible. More importantly: the patient is now completely free of complaints.

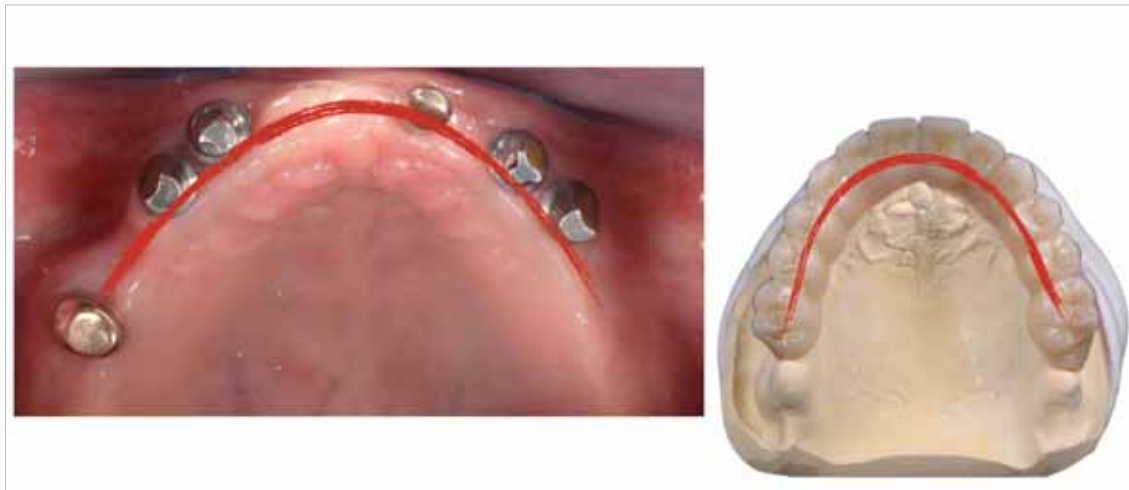
Each patient defines his or her individual solution approach. The prosthetic work team “navigates” safely to the intermediate goal (therapeutic prototype) by capturing the patient-specific information. With the registration of the head posture, the recording of the facial proportions, the model analysis, the analysis of patient-specific movement data and the

presentation of the mandibular position in unmanipulated centrics, it has been possible to align the new prostheses (therapeutic prototype) with the natural occlusal plane.



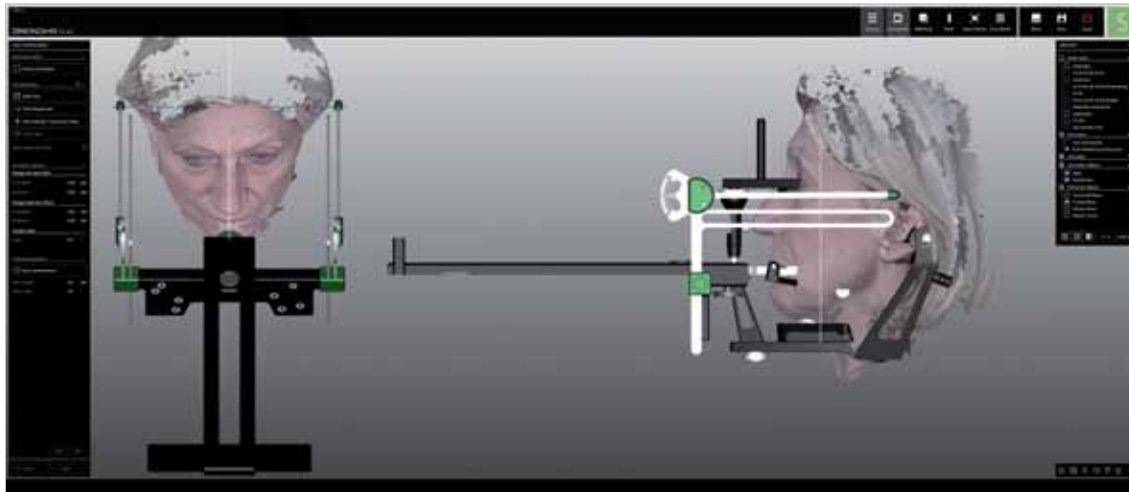
ANALYSIS OF THE THERAPEUTIC PROTOTYPE (2015)

After a longer wearing time, the final dental restoration is planned. The patient feels comfortable with the inserted prototype. She no longer has any physical complaints and indicates that she now has considerably more space for her tongue when speaking.



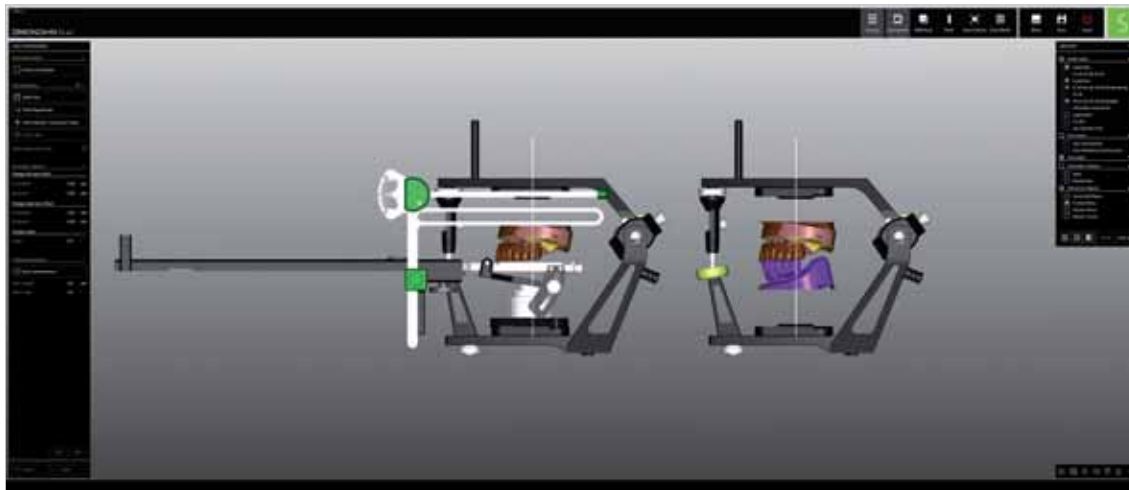
TRANSFER OF THE PROTOTYPE TO THE FINAL RESTORATION

The implants are not optimally positioned. To manufacture the denture on this basis would again narrow the space for the tongue. The resin prototype is grinded very thinly in this area, which is not possible to maintain in the final restoration.



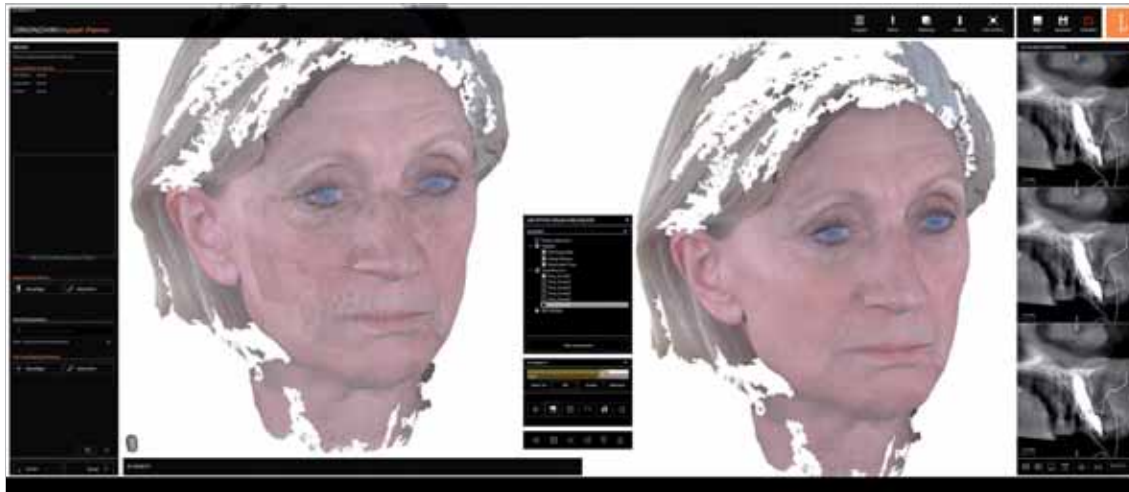
ARTICULATION IN THE SCAN SOFTWARE IN THE CORRECT POSITION

The 3D facial scan created in the dental practice is imported into the Zirkonzahn.Scan software and the skull is positioned in the virtual articulator. For this purpose, the center of the skull and the occlusal plane are set up in the software.*



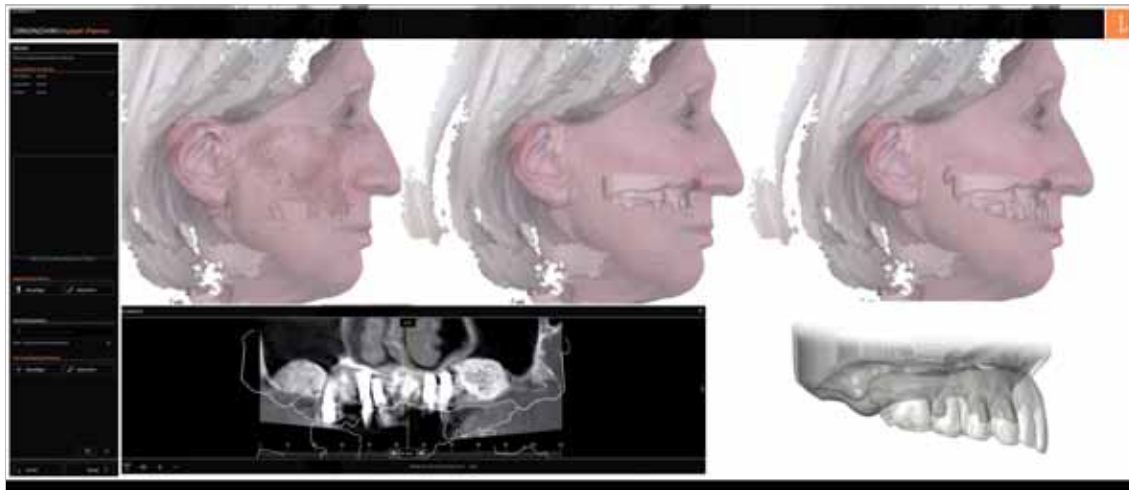
The model pair with digitised prototype is matched with the 3D face scan. Now all patient-specific information is available in the scan software and can be used for virtual planning of the implant positions.

**Face Hunter: Scanner for photorealistic 3-D digitisation of patient faces*



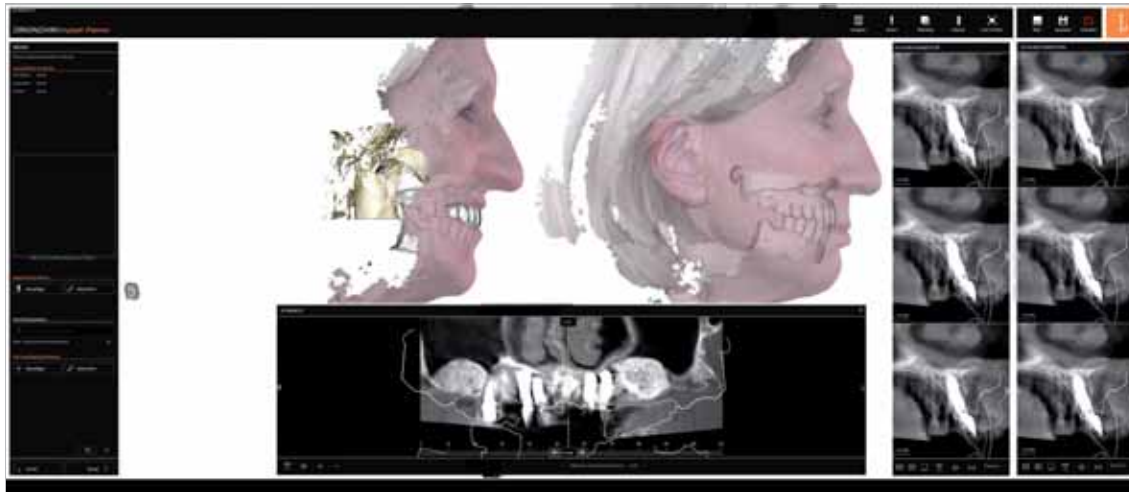ZIRKONZAHN.IMPLANT-PLANNER

The data from the scan software is imported into the implant planning software. This merging of all available patient data offers first-class possibilities for reliable, patient-individual planning. The information validated in advance (diagnostics, analysis) is available digitally and thus serves as an important basis for determining the implant positions.*



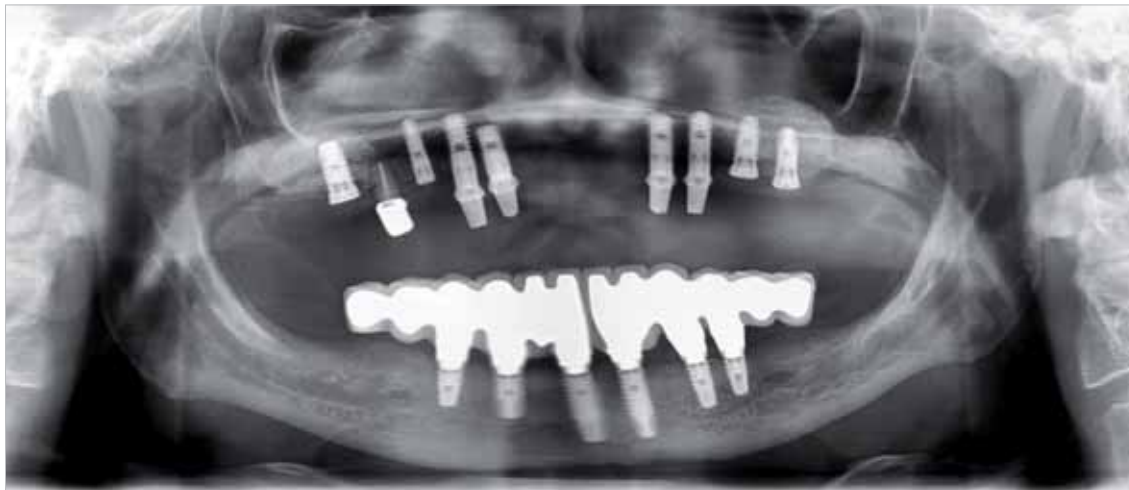The display of the situation model and/or the prototype provides helpful information for the position of the implants (backward planning). The cross-section of the CBCT visualises the anatomic bone situation. The implant planning software can be used to define, among other things, where the transition from bone to tooth restoration should take place.

** Zirkonzahn.Implant-Planner: implant planning software in which all data (CBCT/DICOM, model, facial scan, etc.) are matched.*



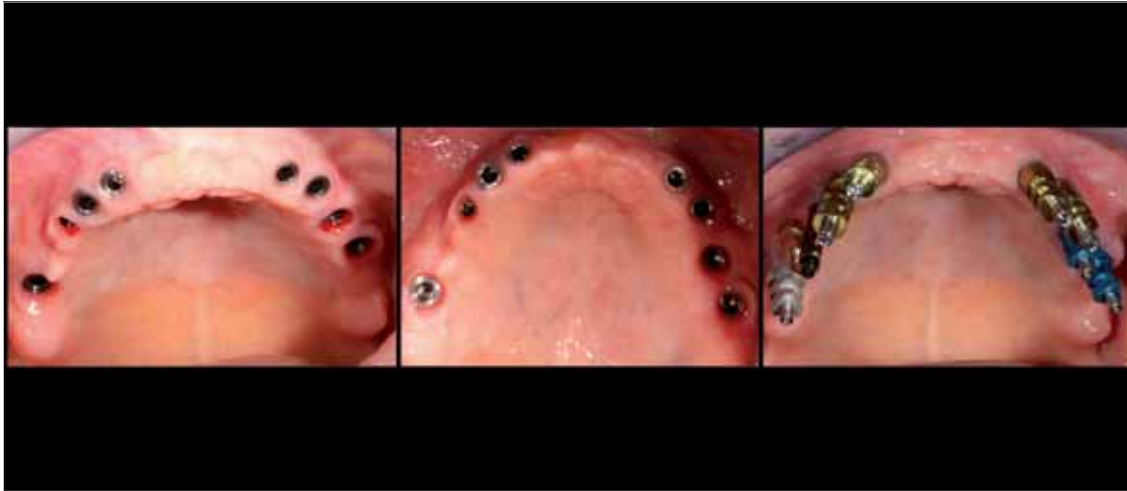3D FACIAL SCAN AND IMPLANT PLANNING

The display of the 3D face scan in combination with the prototype (fine line in CBCT images) generates important information. It becomes clear, for example, how thin the prototype is designed in the palatal area and how little space is available for the restoration. Labially the support requirement of the upper lip profile is shown. CBCT left: Situation while smiling (without upper lip), CBCT right: the upper lip in a relaxed state



ANALYSIS OF THE IMPLANT POSITIONS

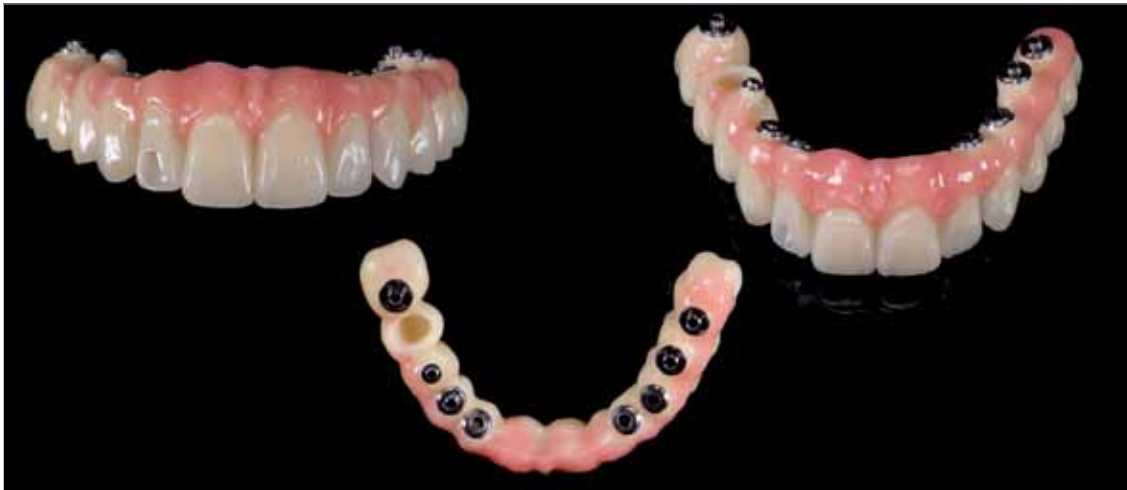Based on the planning, four additional implants (Thommen Medical) were placed in the posterior region of the maxilla and the screw was removed at site 21. The four existing implants in the anterior region are provided with different abutments. Tooth 15 (telescope) is retained for the now for a temporary stabilisation.



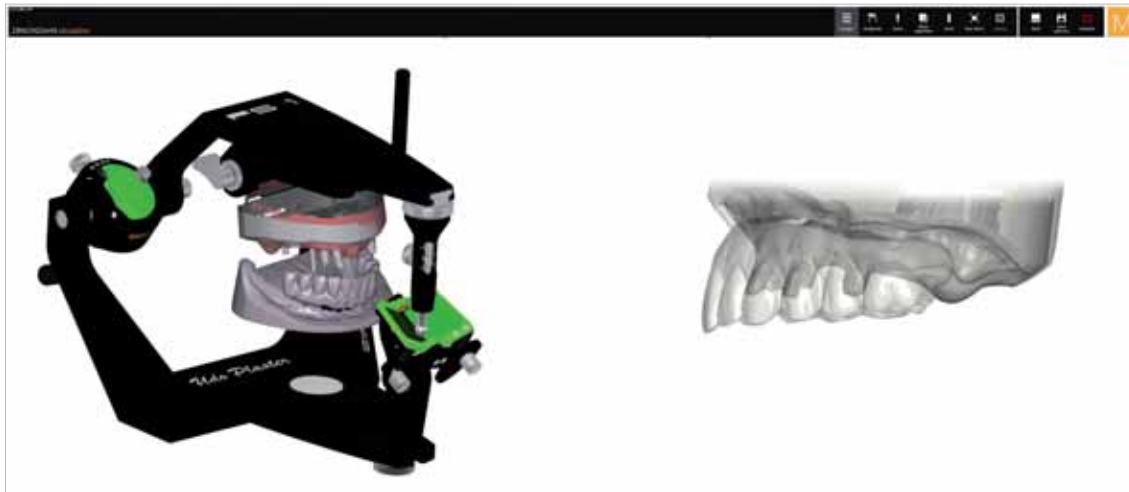
PROTOTYPE 2 – LONG-TERM TEMPORARY RESTORATION (2017)

After osseointegration of the inserted implants in the posterior region, the long-term provisional restoration (prototype 2) for the maxilla is fabricated. The restoration is monolithically milled out of tooth-coloured resin, veneered with composite material and screwed into the mouth.*

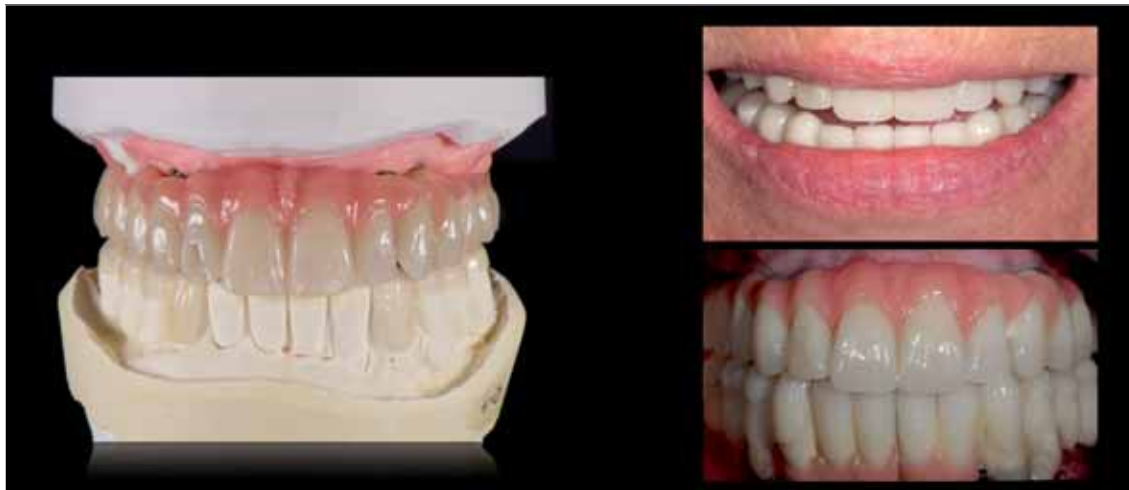**based on the slightly modified prototype 1*



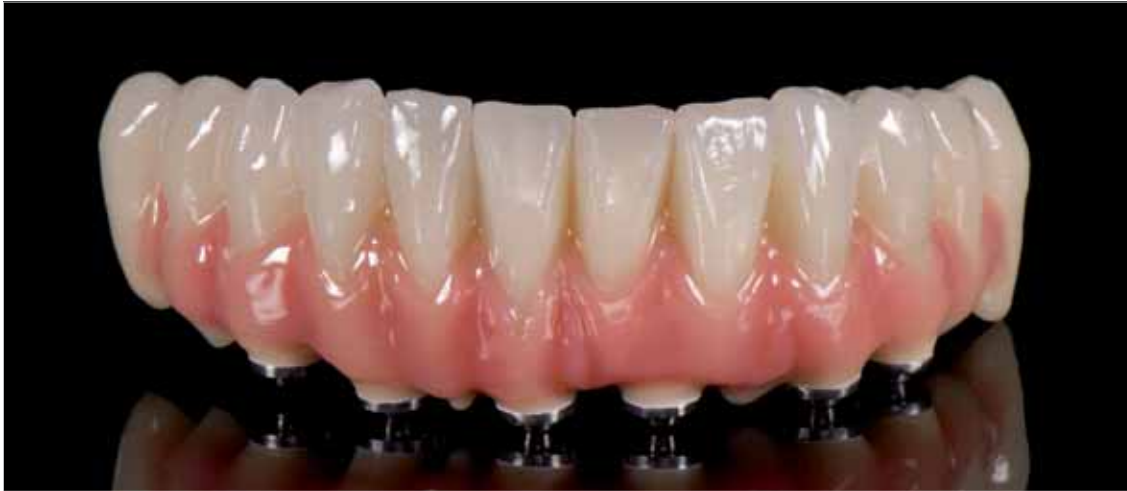Situation before the implant impression



Thanks to the consistent preparatory work, the data set can be used 1:1 for the fabrication of the restoration.

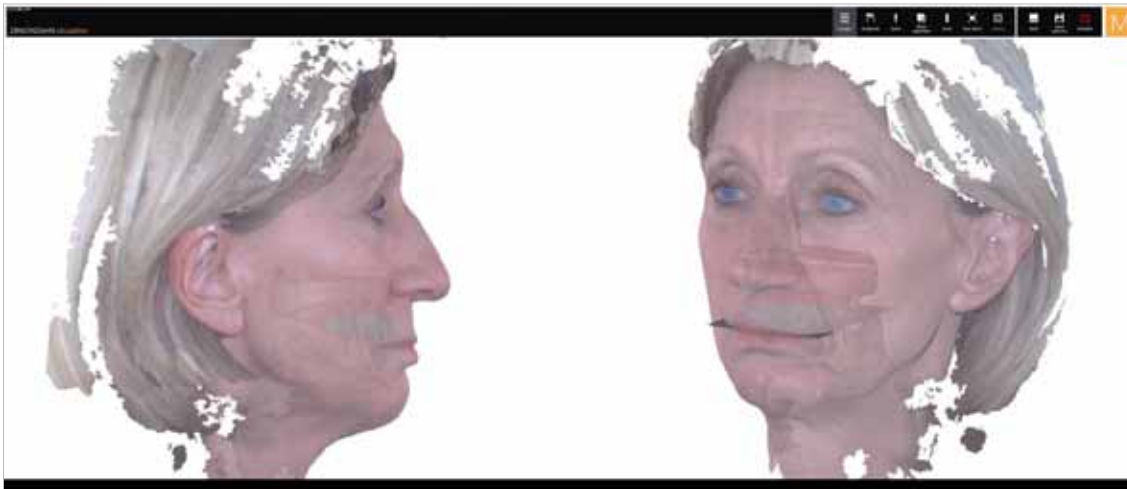


The long-term temporary denture in the upper jaw is screwed onto the implants in the mouth. In the lower jaw, the new composite table-tops are attached to the existing restoration.

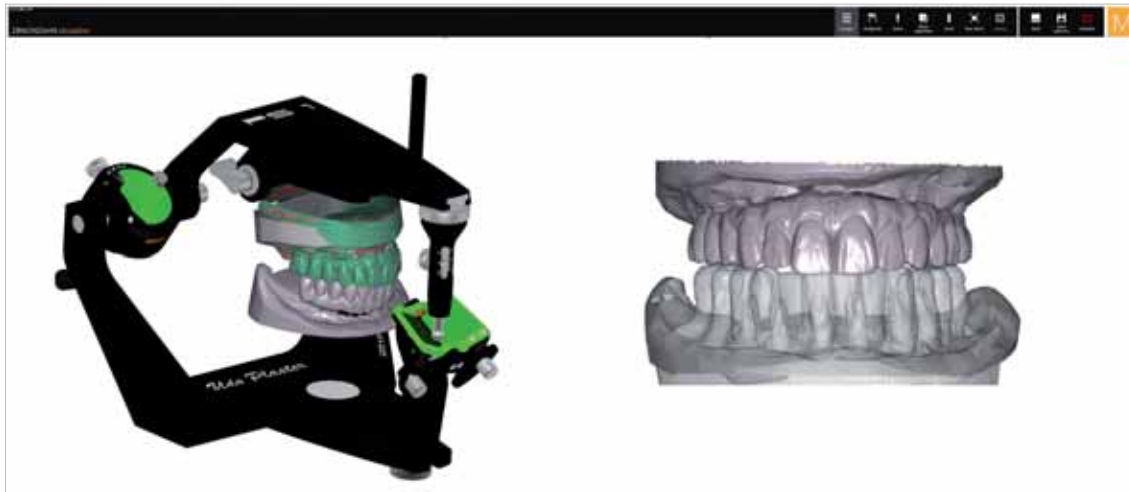


TARGET: PROTOTYPE IN THE LOWER JAW (2018)

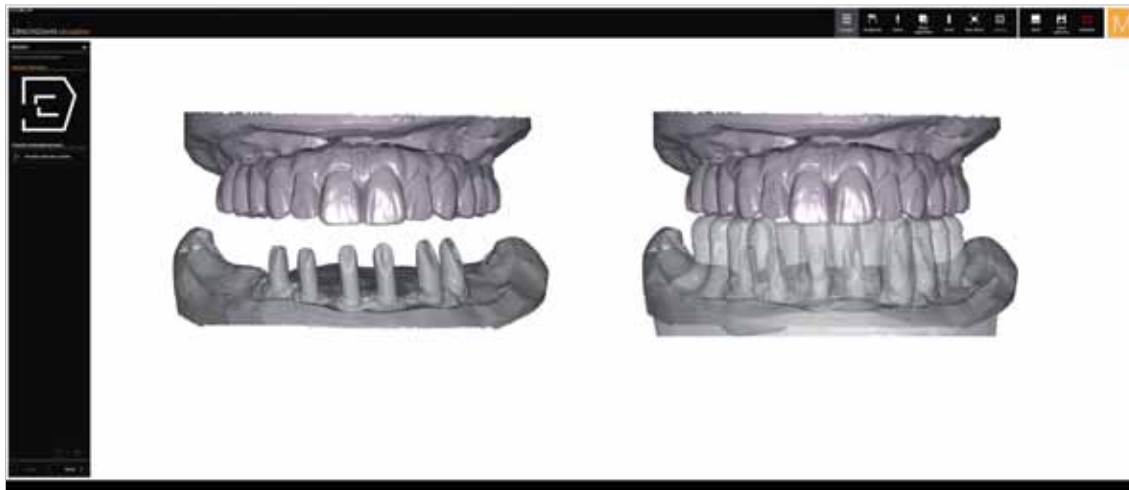
During the therapeutic phase, the patient also decides on a new prosthesis for the lower jaw. Also here, a prototype is produced first.



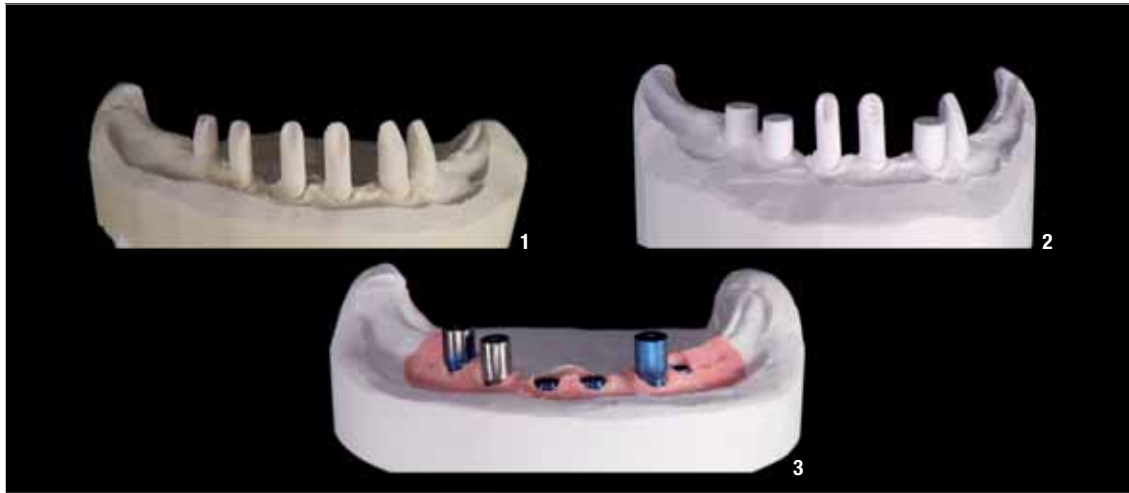
New 3D facial scan with inserted prototype in the upper jaw and the current situation (table-tops) in the lower jaw.



The data sets are imported into the Zirkonzahn.Modellier modelling software.



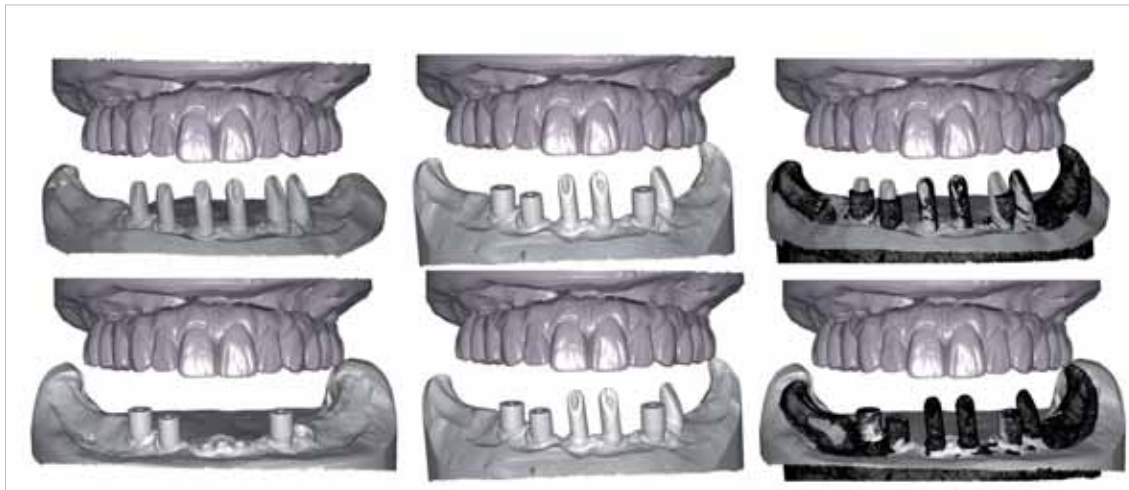
Digital model of the mandible with primary elements (left) and with existing denture as well as table-tops (right) in relation to the maxillary model.



TRANSMISSION OF THE BITE

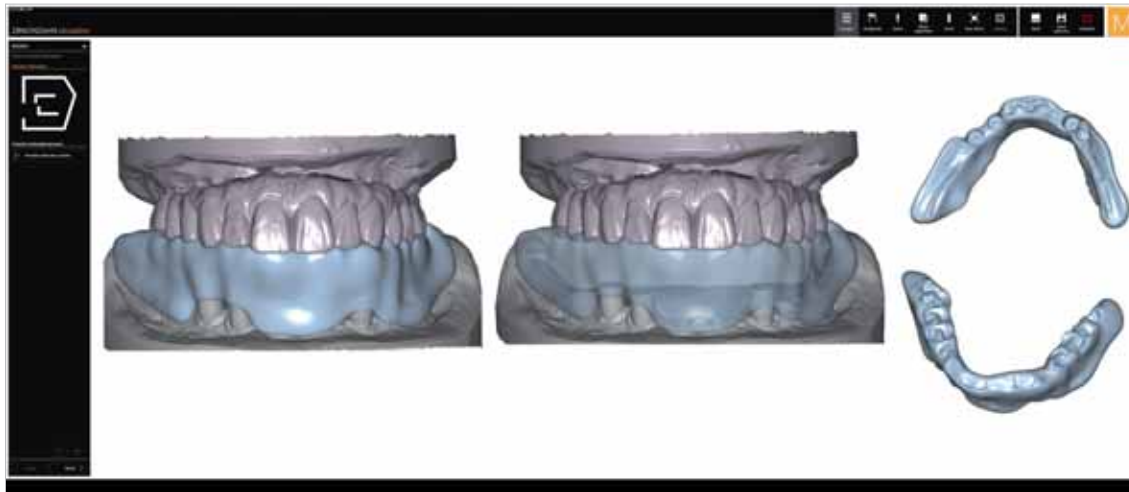The bite is transmitted digitally. Three model situations are available:

- 1. Model with primary parts*
- 2. Model with three healing caps and three primary parts*
- 3. Master model*



SCAN & MATCH

The digitised model with the three healing caps is matched with the existing data set (primary parts). After fixing the healing caps on the master model, it is merged with the final model. In this way, the bite situation or vertical dimension is exactly maintained (see p. 31).

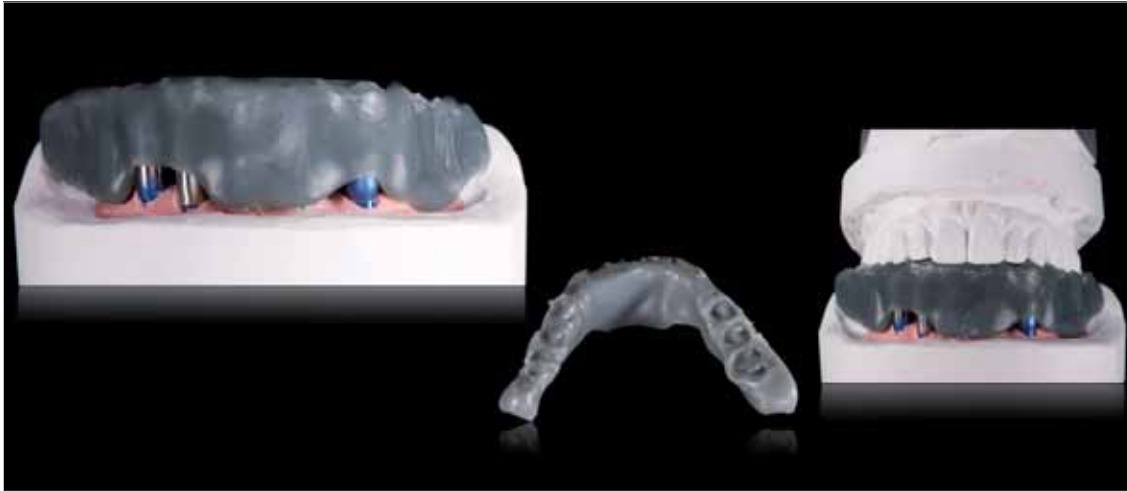

TRANSFER: DIGITAL TO ANALOGUE

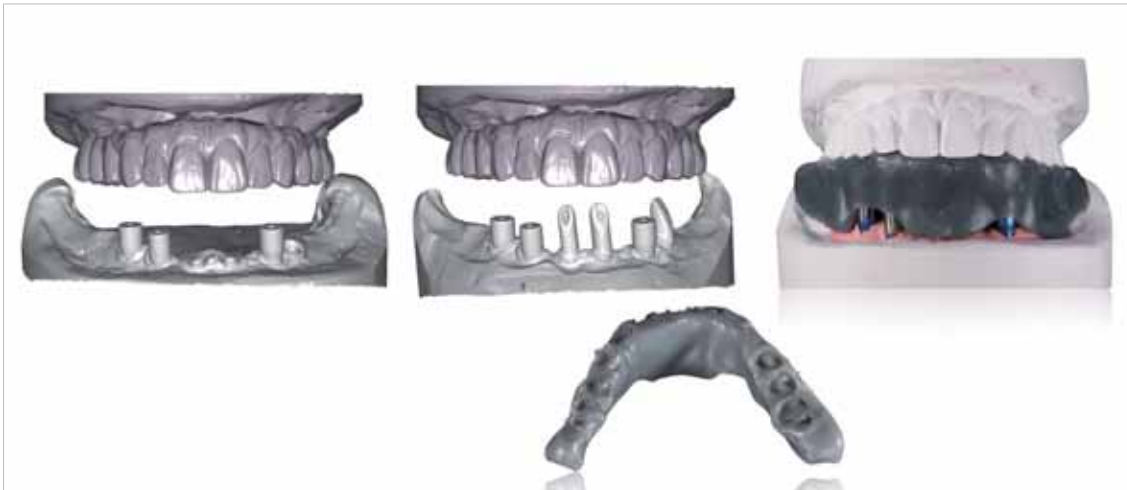In the Zirkonzahn.Modellier software a splint for the lower jaw is created and milled in wax in the Zirkonzahn milling unit.



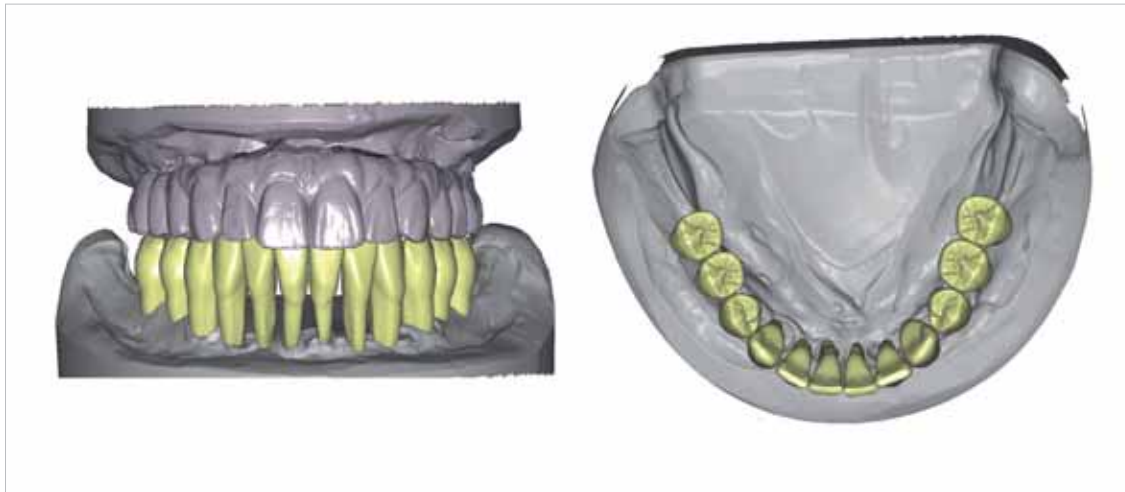
The milled splint for the mandible in the wax blank.



The wax splint on the model and the situation with the mounted upper jaw.

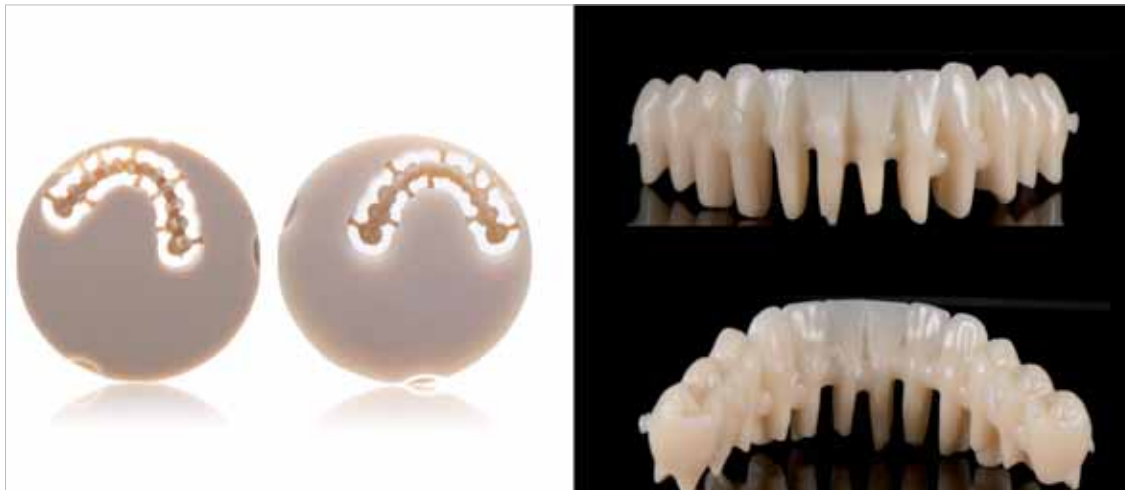

From digital to analogue; the virtual situation is transferred into the analogue world with the help of the wax splint.

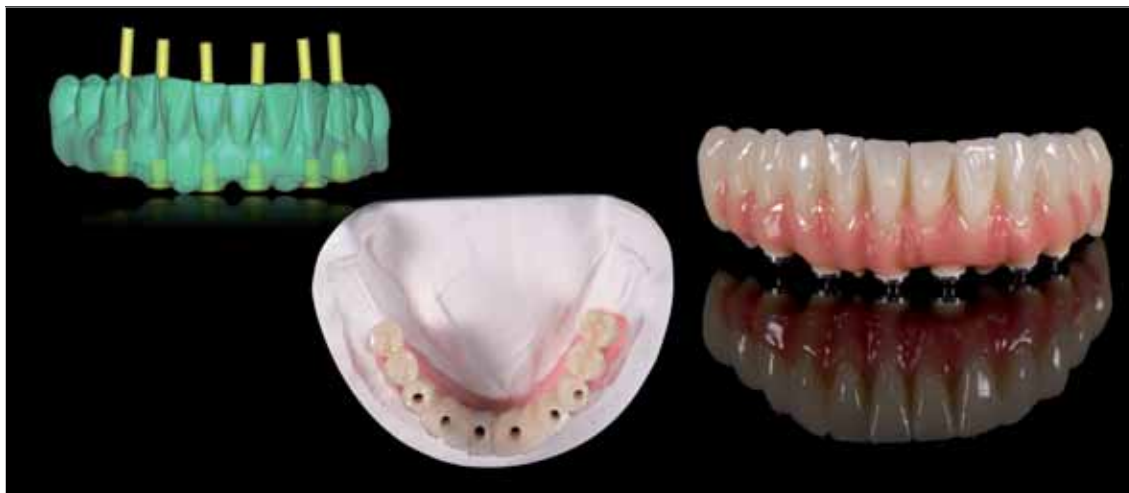

LOWER JAW: ANALYSIS OF TOOTH POSITION AND TOOTH SHAPE

Virtual positioning of the teeth with root parts in the lower jaw. The “Heroes Collection” natural tooth library was used as a basis.

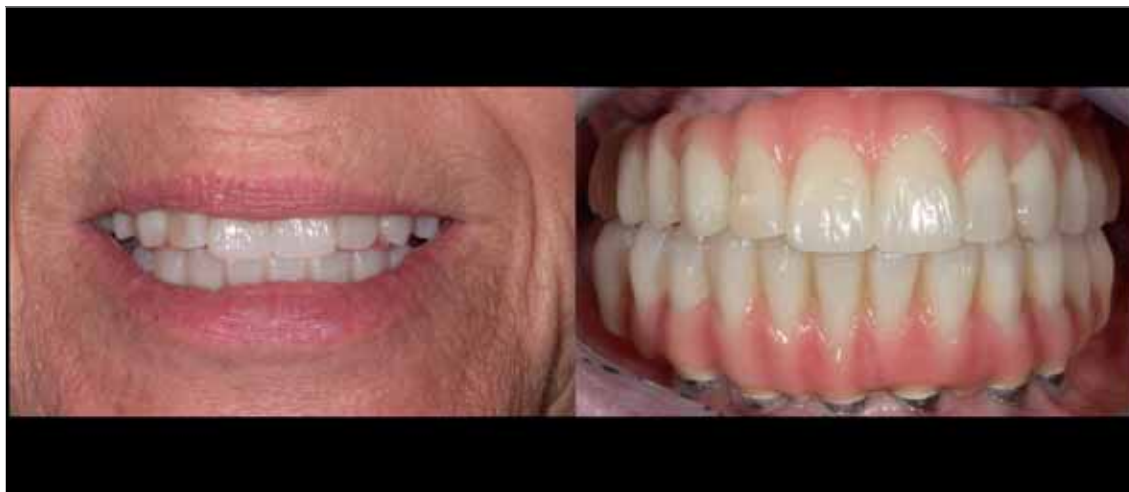

After milling the CAD construction (monolithic) out of a resin blank, the teeth are manually elaborated and grinded into shape.

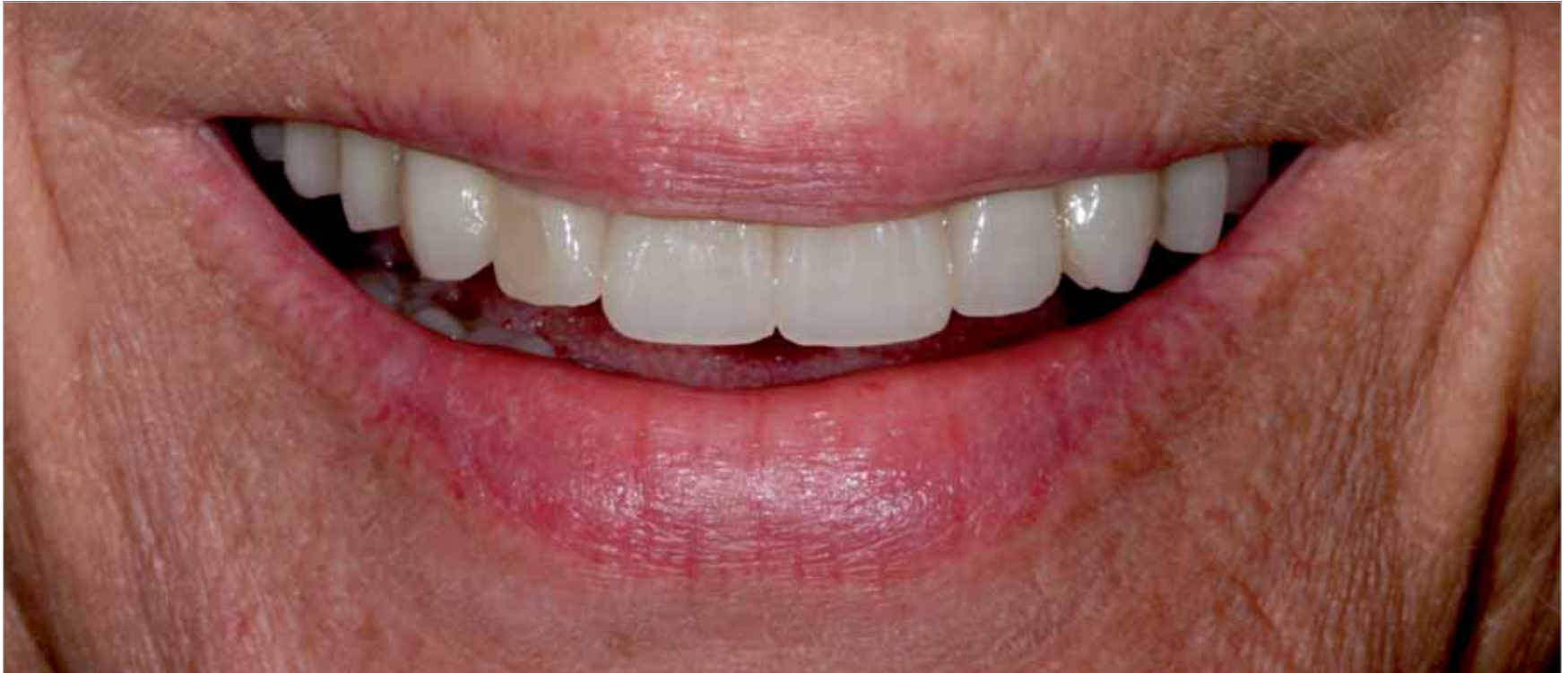

COMPLETION OF THE LOWER JAW PROTOTPYE

The cervical areas are veneered with composite material. The finished restoration can be screwed into the mouth.



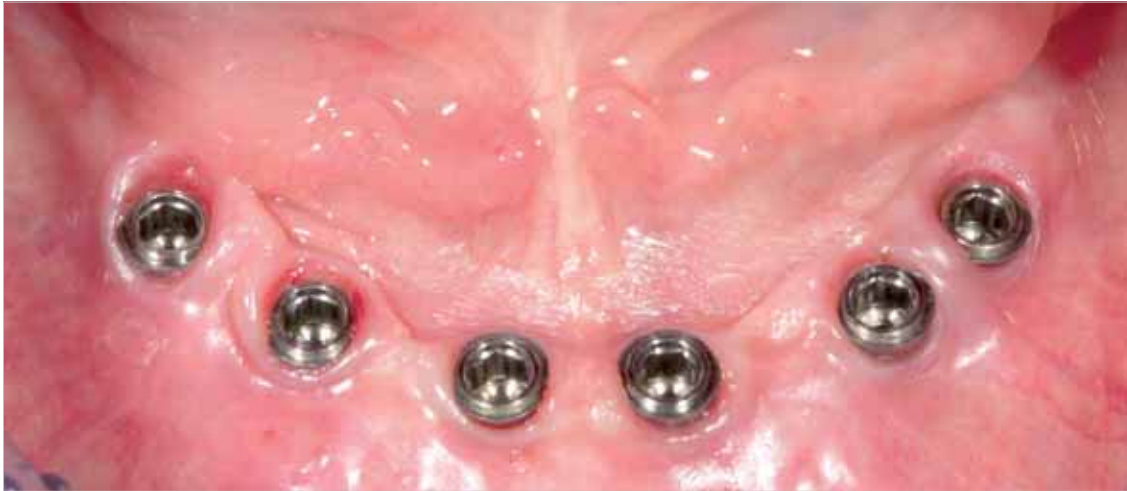The patient wears the prototype 2 (long-term temporary) in the upper jaw and the completed prototype in the lower jaw. The validated bite position has been adopted exactly.



During a wearing period of the long-term temporary in the upper jaw (approx. 12 months) and the lower jaw prototype (approx. six months), the bite position stabilises itself. During this time, the patient checks wearing comfort, hygiene, functional conditions and,

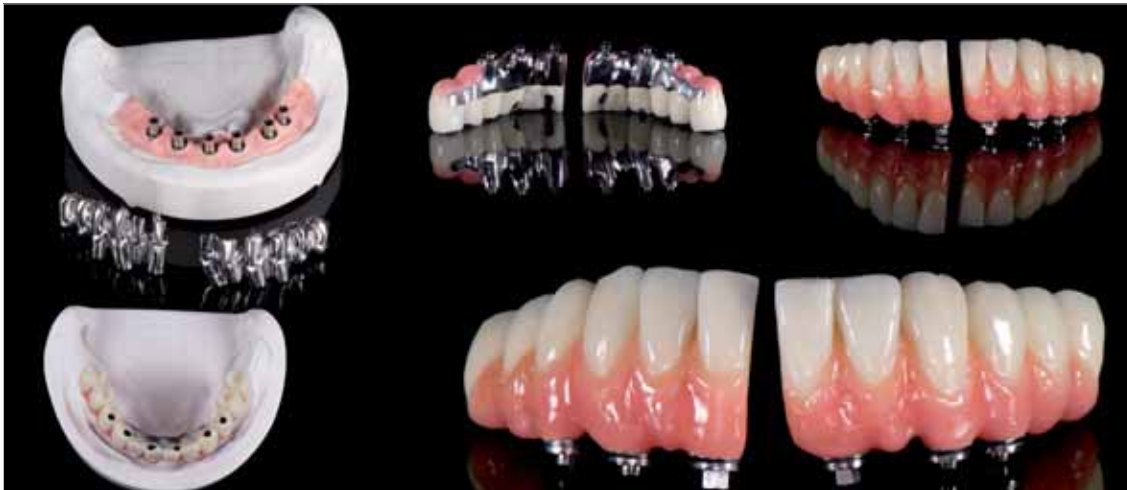of course, aesthetics. Everything is to her satisfaction. Even the phonation is no longer disturbed. She visibly felt comfortable with the restoration and only asked for a slightly lighter shade for the final restoration. The most important thing: She is painless and

has no more tension in the neck area. This stable situation is the optimal time for the fabrication of the final dental prosthesis.



FINAL RESTORATION IN THE LOWER JAW

After removing the prototype from the lower jaw, an implant impression is taken for the fabrication of the final prosthesis. The goal is a titanium framework veneered with composite, which corresponds to the prototype in the vertical dimension.

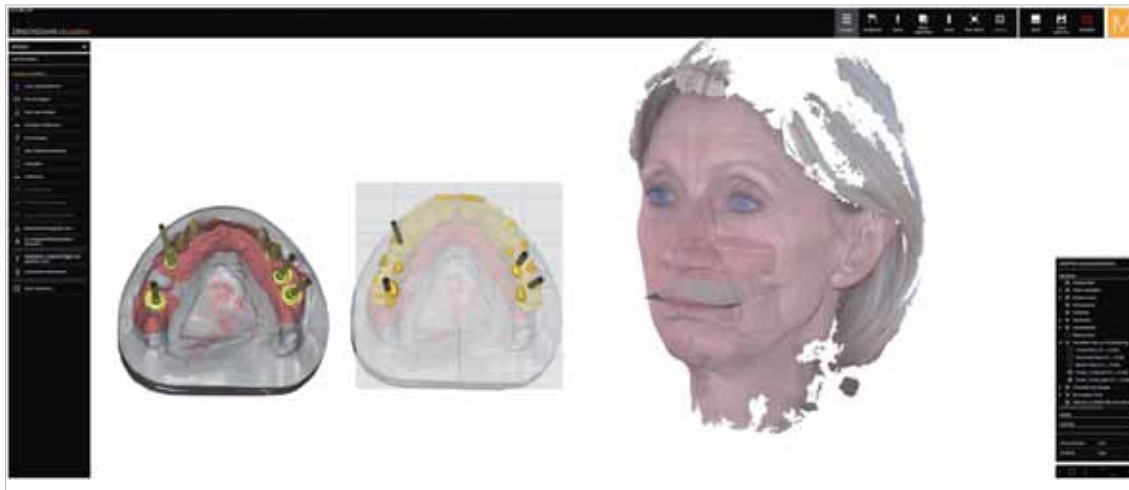


To ensure maximum stability and safety, the titanium framework is manufactured in two parts. The veneering is done with composites.

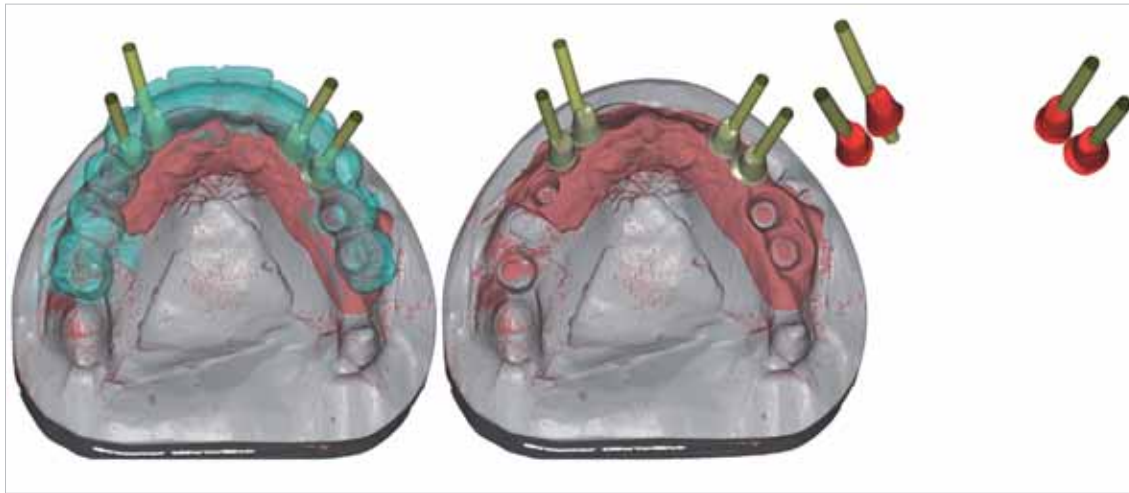


FINAL PROSTHESIS IN THE MAXILLA

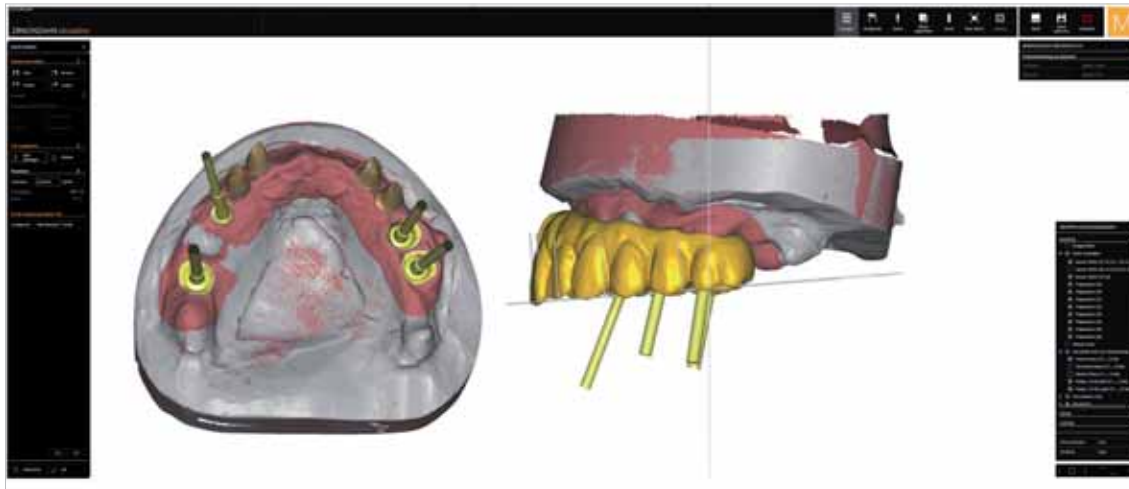
The basis for the framework design in the Zirkonzahn.Modellier software is again the “data pool” with all patient-specific information. A framework made of Prettau® 2 zirconia is to be milled.



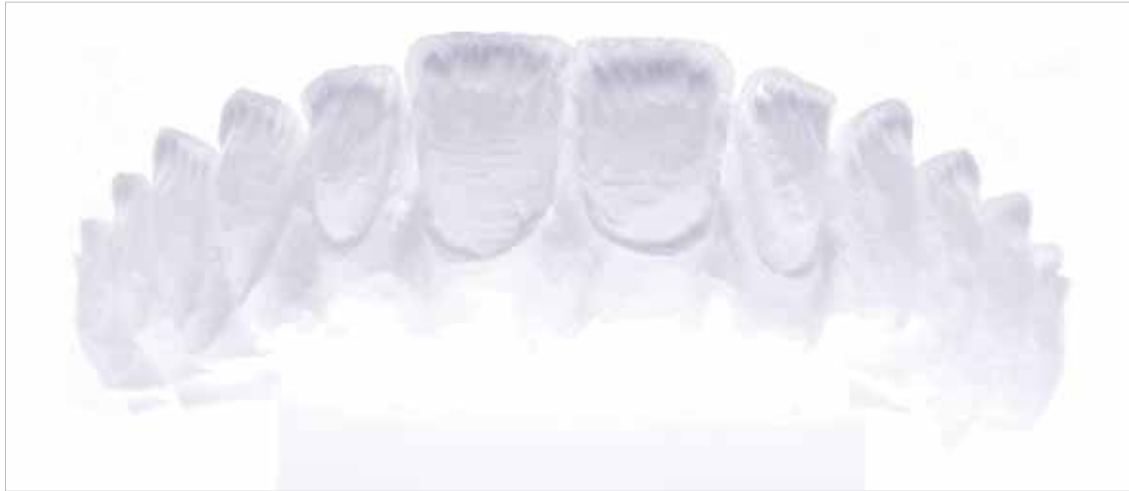For the four implants in the anterior region, primary parts are fabricated on titanium adhesive bases (at the same time abutments).



The data set specifies shape, dimension and inclination for the fabrication of the anterior abutments (primary parts on titanium adhesive bases). No information from the preliminary work has been lost.



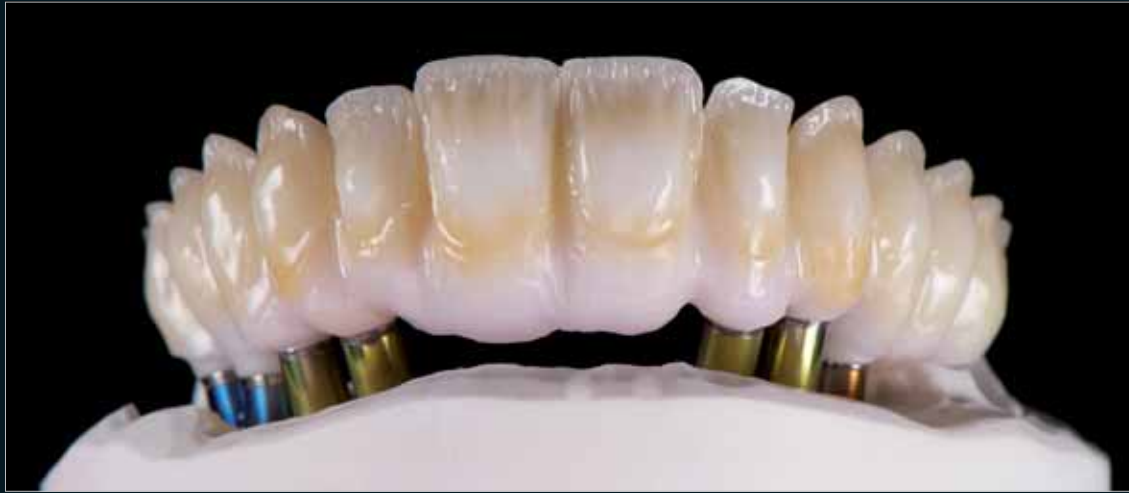The abutments for the posterior implants are fabricated and later screwed directly to the framework. The zirconia framework is milled on the basis of this situation.



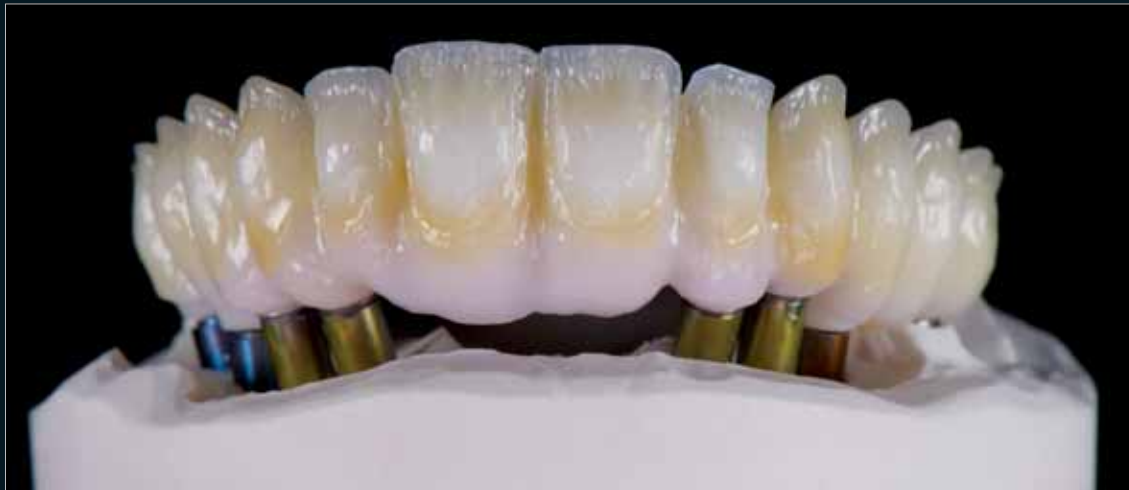The milled Prettau® 2 zirconia framework before colouring and densely sintering.



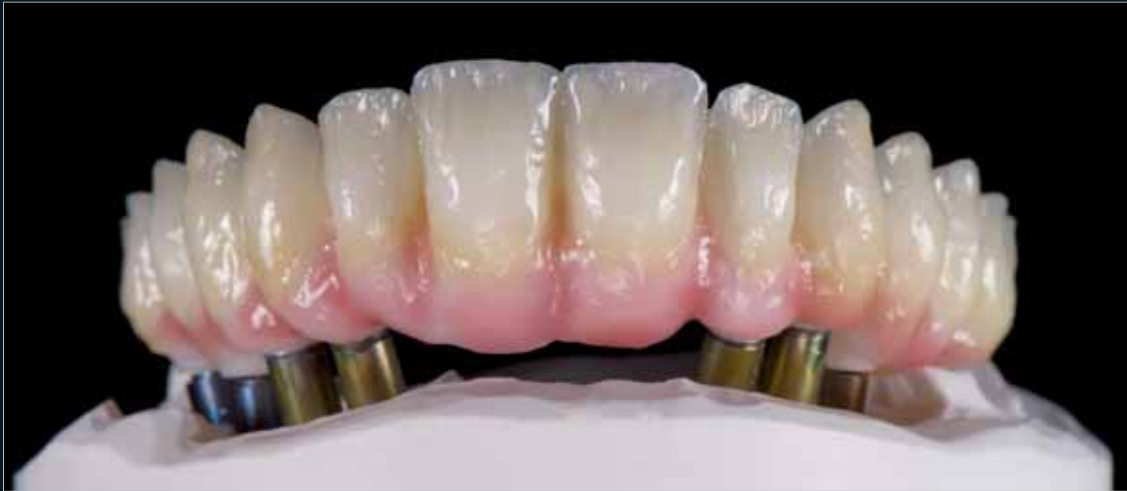Manual colouring of the framework with Colour Liquid Prettau® 2 Aquarell and Intensive colours.



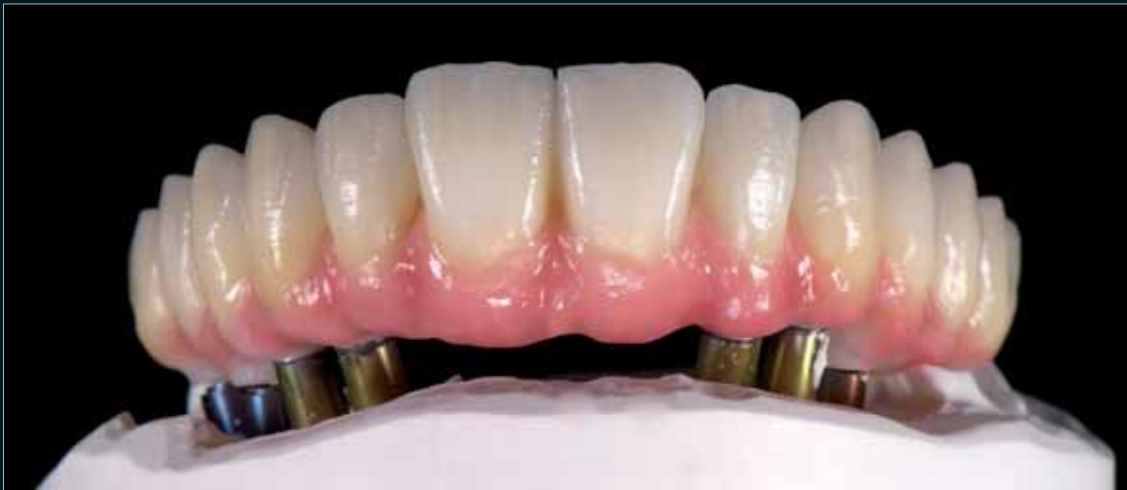The densely sintered framework without any post processing. The perfect colouring base has been created by manual colouring. Only the vestibular areas are veneered. All other components are monolithically designed.



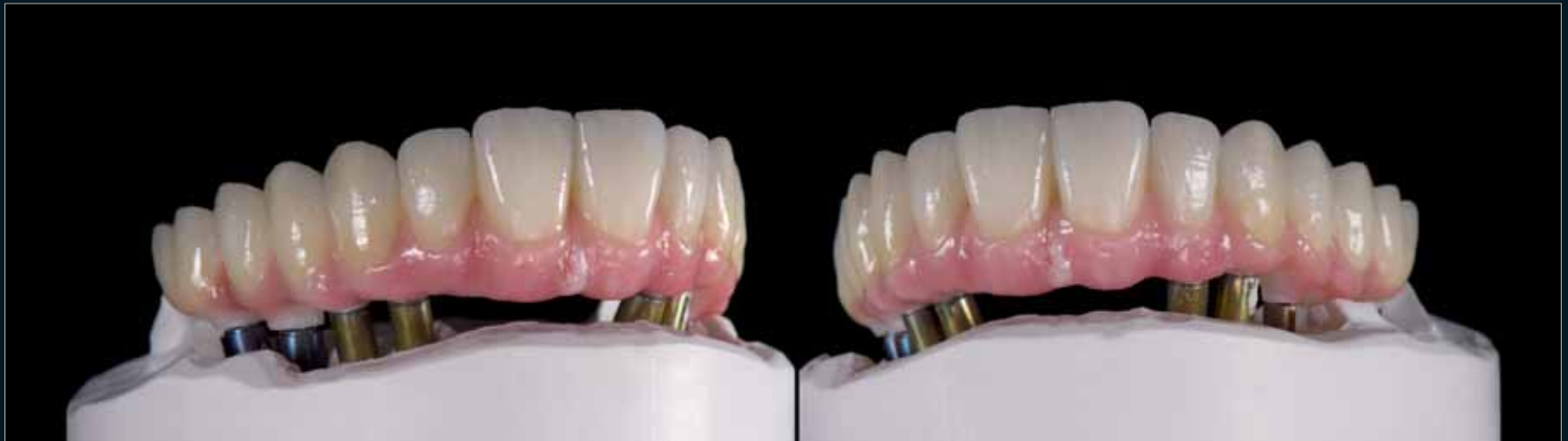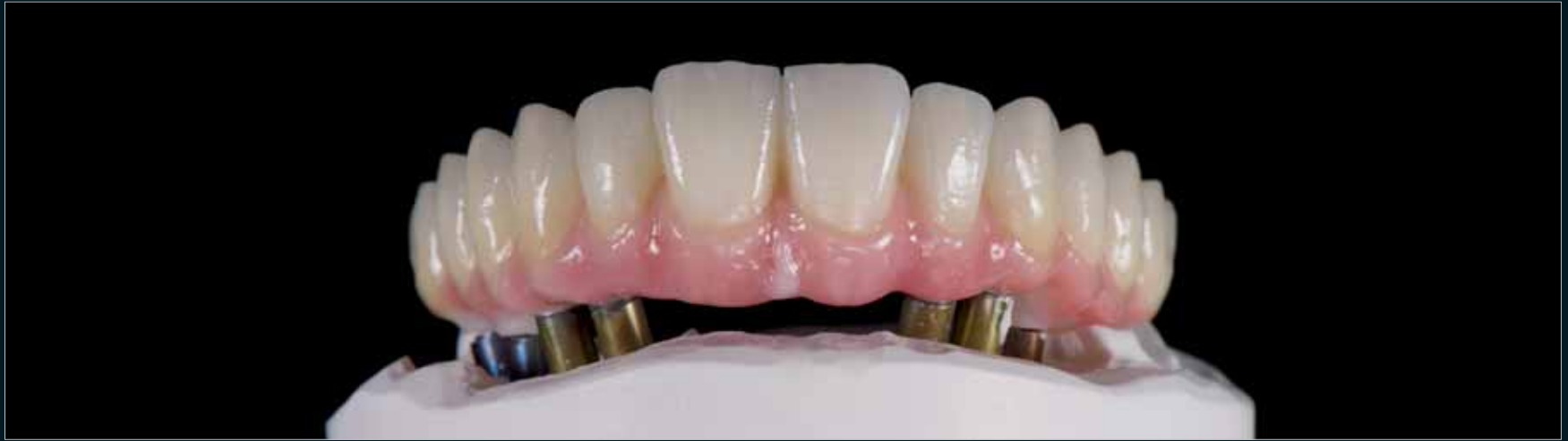Situation after the first firing.

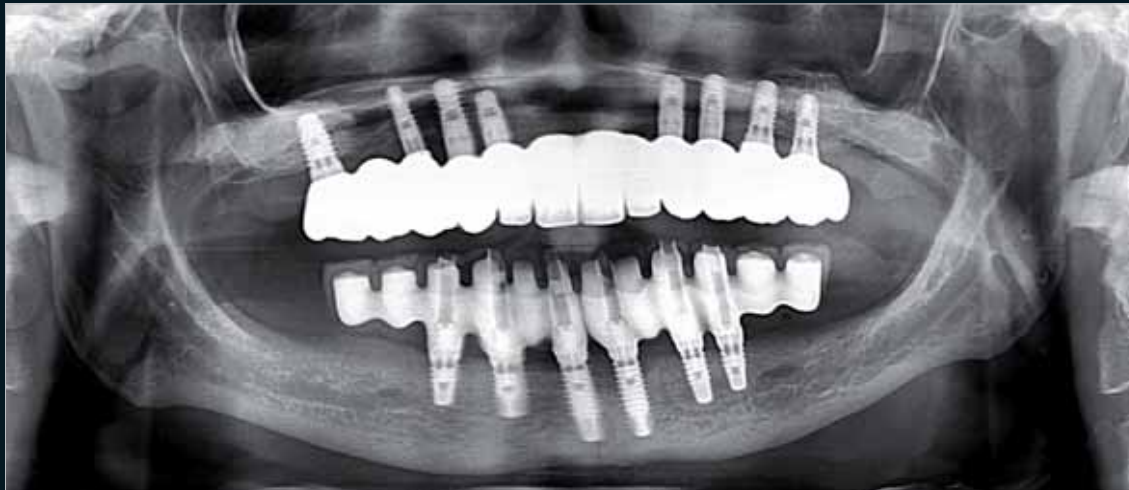
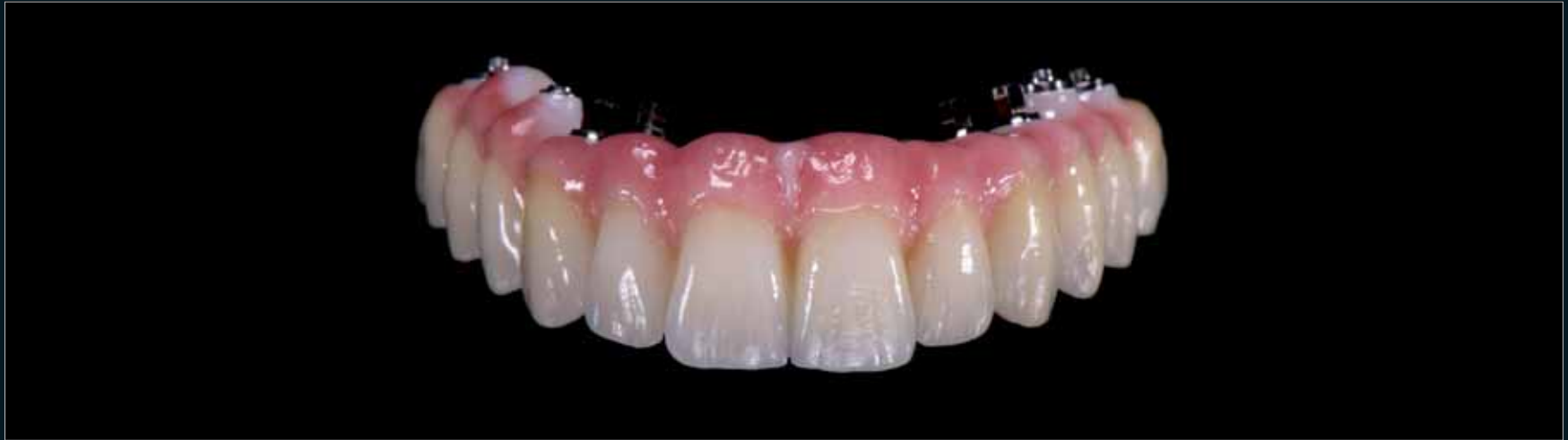

After applying the intensive materials, the materials (teeth and gingiva) are layered and a first dentine firing is carried out.

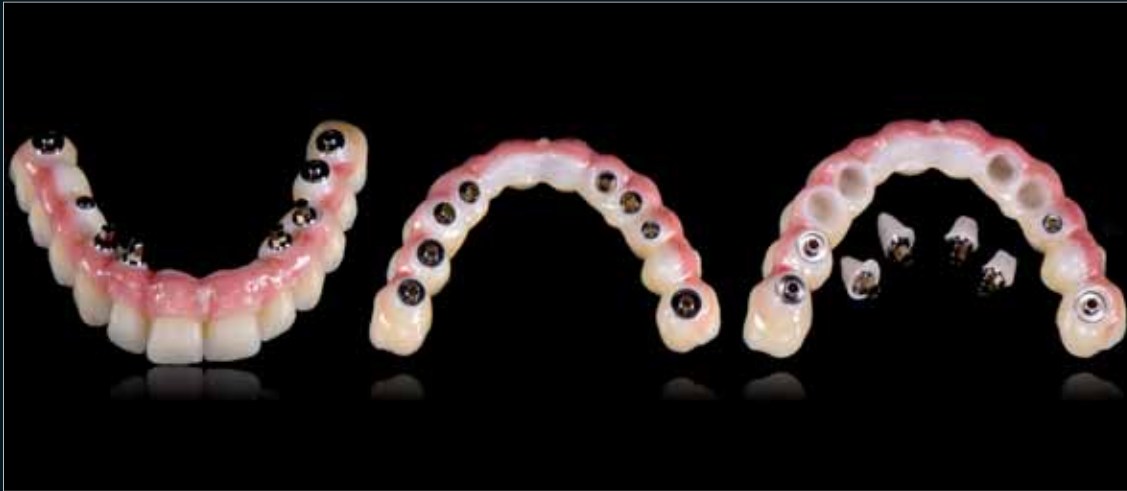

After the correction firing, the restoration is prepared for colouring (not in the labial area) with ICE Zirkon 3D Stains by Enrico Steger and for the final glaze firing.

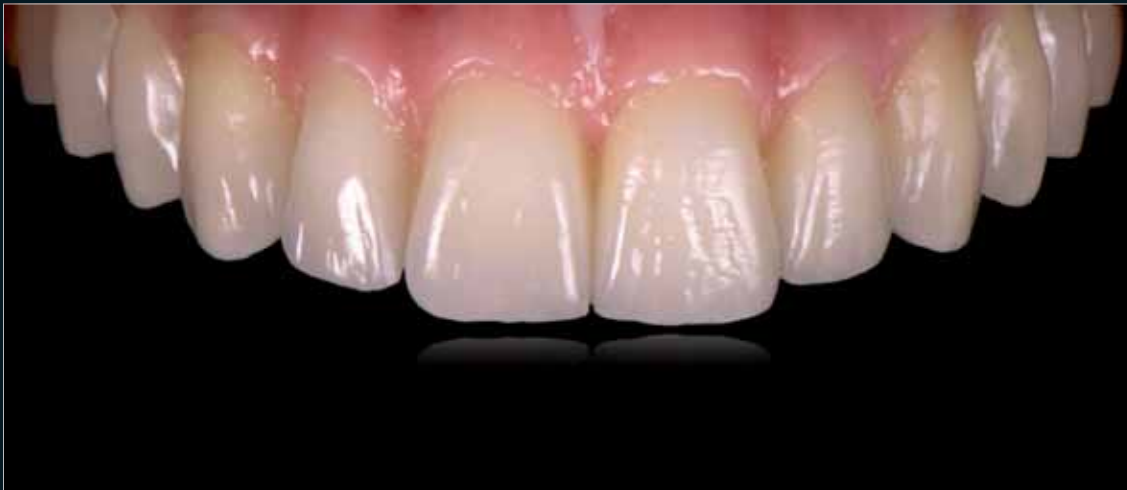



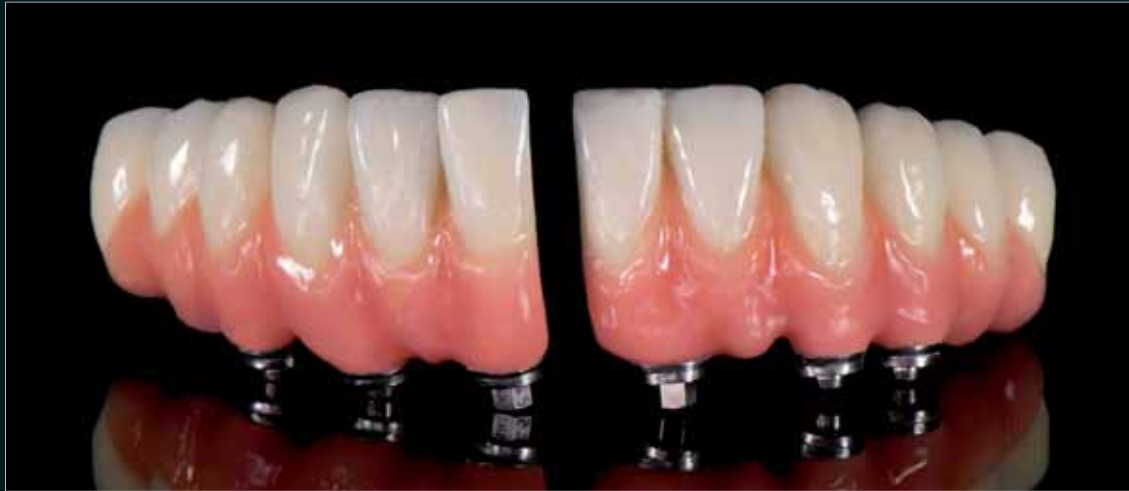X-ray of the final restoration: Prettau® 2 zirconia restoration in the maxilla and titanium framework with composite veneering in the mandible.



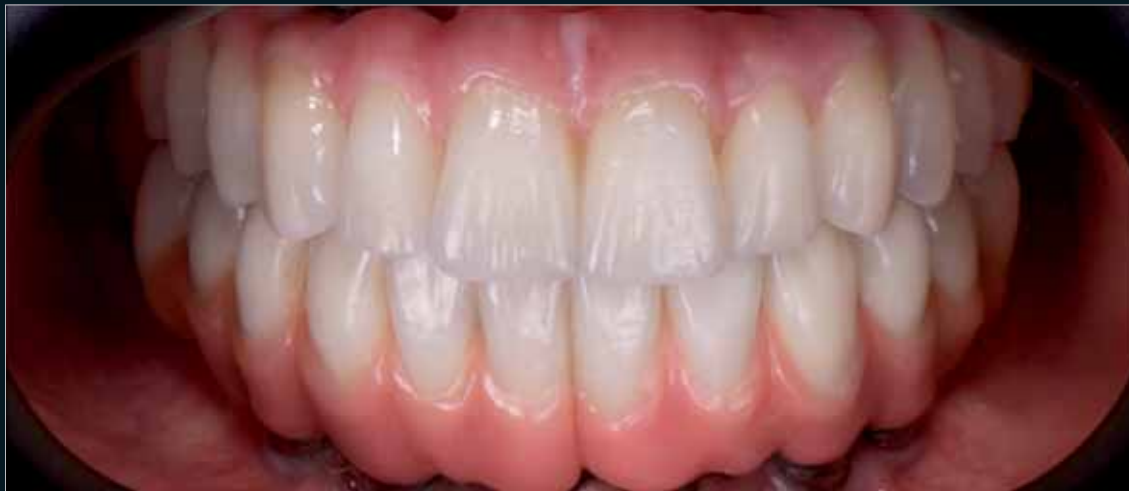The finished restoration in the maxilla with the ceramic abutments (primary elements) for the anterior implants. The posterior abutments are screwed onto the restoration in the mouth.



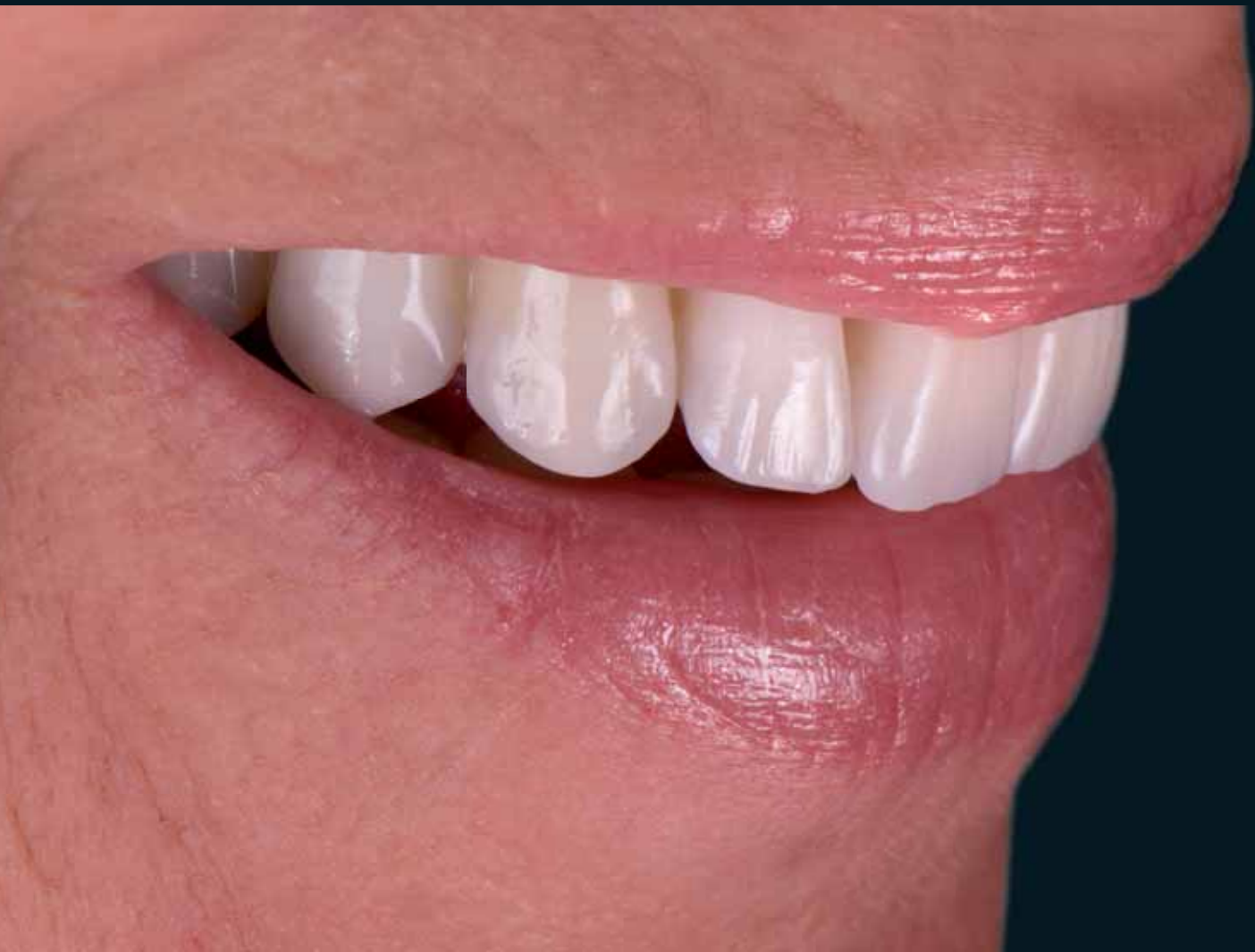Restoration made of Prettau® 2 zirconia: the zirconia framework in the maxilla is veneered in the vestibular region, while the occlusal and palatal portions are monolithic.

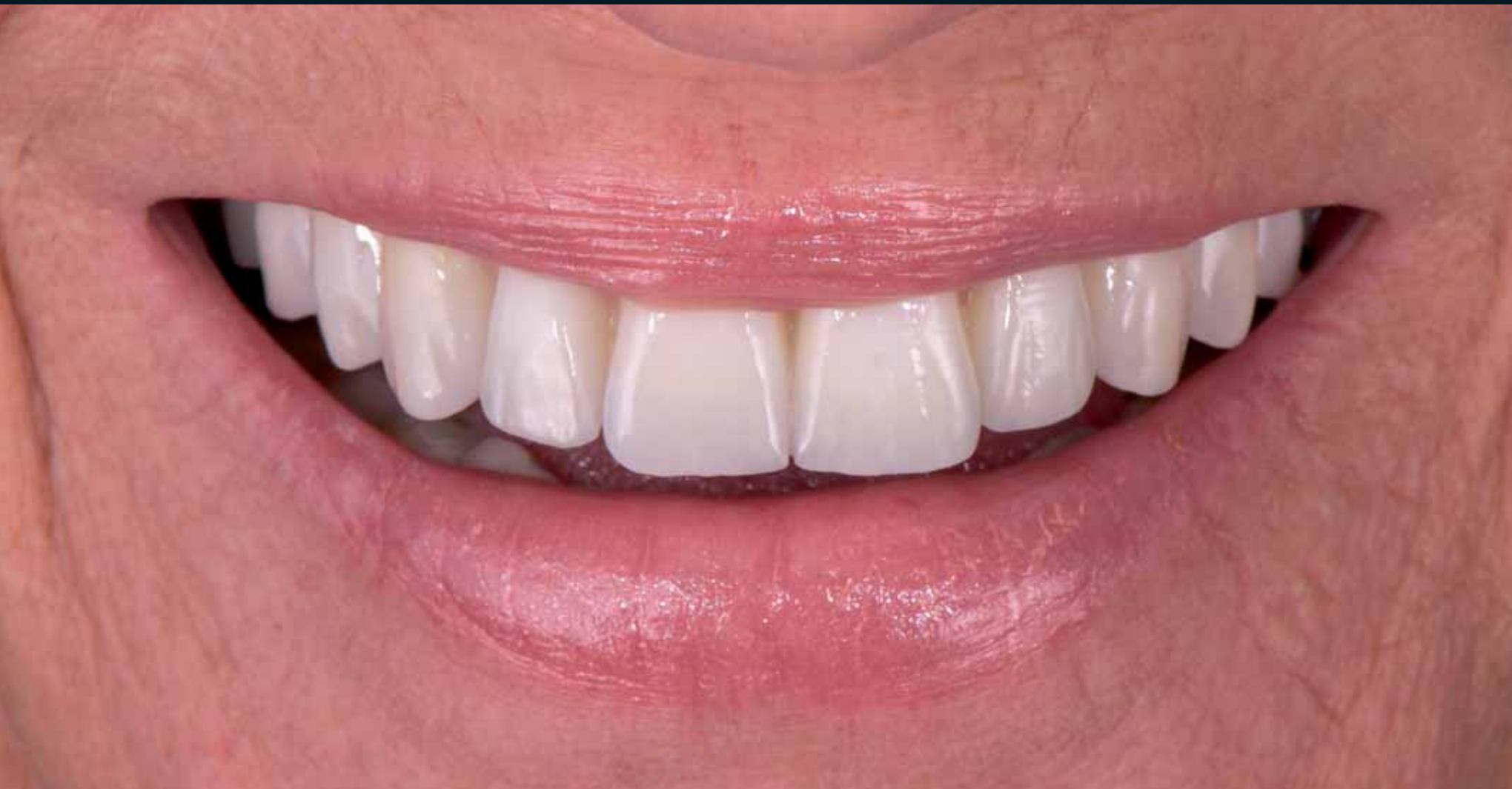

The split restoration in the mandible before screwing into the mouth. The titanium framework has been veneered with composite.



The final restoration in situ.









Zirkonzahn®



PLANESYSTEM®

*Zirkonzahn Worldwide – Via An der Ahr 7 - 39030 Gais/South Tyrol
T +39 0474 066 680 – F +39 0474 066 661 – www.zirkonzahn.com – info@zirkonzahn.com*

ENGLISH



WEAB8108EN=

All information is subject to change. Errors and omissions excepted. Version: 22/05/2019